

# Western Trauma Association/Critical Decisions in Trauma: Operative Management of Adult Blunt Hepatic Trauma

Rosemary A. Kozar, MD, PhD, David V. Feliciano, MD, Ernest E. Moore, MD, Frederick A. Moore, MD, Christine S. Cocanour, MD, Michael A. West, MD, James W. Davis, MD, and Robert C. McIntyre, Jr., MD

**Key Words:** Hepatic trauma, Operative hepatic trauma, Algorithm.

(*J Trauma*. 2011;71: 1–5)

This is a recommended algorithm of the Western Trauma Association for the operative management of blunt hepatic injuries. Because there are few published prospective randomized trials, the recommendations are based on available published prospective, observational, and retrospective data and expert opinion of Western Trauma Association members. The algorithm (Fig. 1) and accompanying text represent reasonable treatment strategies that could be followed at most trauma centers. We recognize that there will be variability in decision-making and institutional and patient-specific factors that may warrant deviation from the recommended algorithm. We encourage institutions to use this algorithm as a basis to develop institution-specific protocols.

The algorithm contains letters that correspond to the text. Their purpose is to explain the critical factors affecting decisions and to guide the reader through the algorithm.<sup>1</sup>

Submitted for publication February 27, 2010.

Accepted for publication April 20, 2011.

Copyright © 2011 by Lippincott Williams & Wilkins

From the Department of Surgery (R.A.K.), University of Texas Health Science Center at Houston, Houston, Texas; Department of Surgery (D.V.F.), Grady Memorial Hospital, Atlanta, Georgia; Department of Surgery (E.E.M.), Denver Health Medical Center, Denver, Colorado; Department of Surgery (F.A.M.), The Methodist Hospital, Houston, Texas; Department of Surgery (C.S.C.), University of California Davis, Sacramento, California; Department of Surgery (M.W.), San Francisco General Hospital, San Francisco, California; Department of Surgery (J.W.D.), UCSF Fresno, Fresno, California; Department of Surgery (R.M.), University of Colorado Health Science Center, Denver, Colorado.

The Western Trauma Association (WTA) develops algorithms to provide guidance and recommendations for particular practice areas, but does not establish the standard of care. The WTA develops algorithms based on the evidence available in the literature and the expert opinion of the task force in the recent timeframe of the publication. The WTA considers use of the algorithm to be voluntary. The ultimate determination regarding its application is to be made by the treating physician and health care professionals with full consideration of the individual patient's clinical status and available institutional resources and is not intended to take the place of health care providers' judgment in diagnosing and treating particular patients.

Presented at the 40th Annual Meeting of the Western Trauma Association, February 28 to March 5, 2010, Telluride, Colorado.

Address for reprints: Rosemary Kozar, MD, PhD, Department of Surgery, University of Texas Health Science Center at Houston, 6431 Fannin, MSB 4.284, Houston, TX 77030; email: rosemary.a.kozar@uth.tmc.edu.

DOI: 10.1097/TA.0b013e318220b129

*The Journal of TRAUMA*® Injury, Infection, and Critical Care • Volume 71, Number 1, July 2011

References to support each step are inserted as appropriate. No attempt is made to describe the proposed techniques, but rather to guide the reader through an organized approach to the bleeding patient with a complex hepatic injury requiring operative intervention. As experience with operative intervention is diminishing, familiarity with operative techniques is of paramount importance. Lucas and Ledgerwood<sup>2</sup> recently reported that a fully trained surgical resident would perform some type of hemostatic technique to control liver bleeding only 1.2 times by completion of their residency.

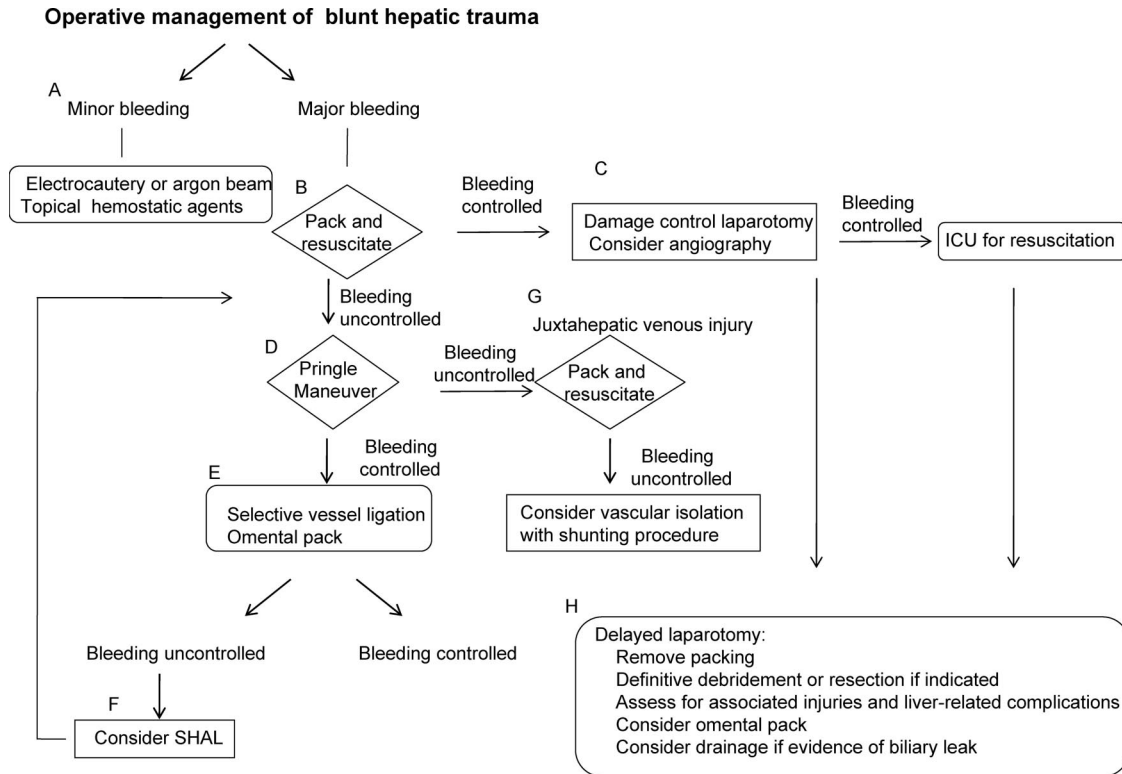
## HISTORY OF OPERATIVE MANAGEMENT OF BLUNT HEPATIC TRAUMA

Over the past 2 decades, treatment of blunt hepatic injuries has changed dramatically. A shift away from operative management has occurred with a resultant decline in mortality.<sup>3</sup> Richardson et al. attributed improved survival to less patients with major venous injuries requiring operative intervention, improved outcomes with venous injuries, better results with packing, and control of arterial hemorrhage by angioembolization.<sup>4</sup> A recent review of the National Trauma Database demonstrated that only 13.7% of hepatic injuries are now managed operatively.<sup>5</sup> As the primary indication for operative intervention is hemodynamic instability, trauma surgeons are faced with managing exsanguinating hemorrhage from complex hepatic injuries.

Table 1 summarizes some of the major milestones in operative strategies.<sup>6–22</sup> Attempts were made to include the original description for trauma. We acknowledge that not all important advances or contributing surgeons are included.

## ANNOTATED TEXT FOR ALGORITHM

- A. Minor liver bleeding is most often due to grade I and II liver injuries and can frequently be managed by packing alone. If needed, simple techniques such as electrocautery or argon beam coagulation or topical hemostatic agents can be used as adjuncts. Although rarely required, continued bleeding may warrant repacking and temporary abdominal closure.
- B. The first step in the management of patients with major hepatic hemorrhage is manual compression. During this time, the surgeon compresses the injured parenchyma between two hands to allow clotting to occur. The patient should undergo intraoperative resuscitation with blood



**Figure 1.** Algorithm for operative management of blunt liver trauma. ICU, intensive care unit; SHAL, selective hepatic artery ligation.

**TABLE 1.** Milestones in the Operative Management of Blunt Hepatic Injuries

Authors	Technique
Pringle <sup>6</sup>	Occlusion of porta hepatis
Madding <sup>7-9</sup>	Suture repair, resection, and vessel ligation
McClelland et al. <sup>10</sup>	Anatomic resection
Aaron et al. <sup>11</sup>	Hepatic artery ligation
Schrock et al. <sup>12</sup>	Atriocaval shunt
Lin <sup>13</sup>	Finger fracture for cancer
Pachter and Spencer <sup>14</sup>	Finger fracture for trauma
Stone and Lamb <sup>15</sup>	Omental pack
Lucas and Ledgerwood <sup>16</sup>	Hepatic packing
Calne et al. <sup>17</sup>	
Feliciano et al. <sup>18</sup>	
Elerding et al. <sup>19</sup>	“Bloody vicious cycle”
Kashuk et al. <sup>20</sup>	
Stone et al. <sup>21</sup>	Staged laparotomy
Burch et al. <sup>22</sup>	

component therapy according to institutional guidelines. Activation of a massive transfusion protocol should be strongly considered as early activation has been shown to reduce mortality.<sup>23</sup> In addition, prevention and correction of hypothermia and acidosis should be instituted. Patients receiving massive transfusion are also at risk for hypocalcemia, which results from binding of calcium by citrate found in stored blood. With rapid infusion of blood or

with impaired hepatic function, hypocalcemia secondary to citrate toxicity can occur.<sup>24</sup> Finally, a rapid and systematic abdominal exploration should be performed to identify sources of nonhepatic hemorrhage and areas of contamination. Perihepatic packing will control bleeding in most patients when done correctly and expeditiously.<sup>25</sup> Laparotomy pads are placed around the liver to both compress the injury and to assist in hemostasis. Some surgeons advocate mobilization of the liver for optimal placement of packs, although this does have the potential to increase bleeding if not done correctly. Importantly, definitive management of the liver injury is not performed at the initial surgery, rather packing is left in place, a temporary abdominal closure is performed, and the patient is transported to the intensive care unit (ICU) for resuscitation. Although most applicable for penetrating trauma with deep tracts into the liver parenchyma, balloon tamponade using a Penrose or Foley catheter can be a useful adjunct to control exsanguinating hemorrhage in patients not responding to packing alone.<sup>26</sup>

C. The concept of damage control was introduced by Stone et al.<sup>21</sup> in the 1980s and promulgated by the group at Ben Taub in 1992.<sup>22</sup> This came after the report by Denver General that in patients sustaining fatal hepatic hemorrhage after trauma, hemostasis was not possible as patients were hypothermic, acidotic, and receiving large volumes of packed red cells before blood component or fresh blood.<sup>19</sup> This led to the concept of the “bloody

vicious cycle.”<sup>20</sup> The term “damage control” was popularized by the group at the University of Pennsylvania in the 1993.<sup>27</sup> They described initial control of hemorrhage and contamination followed by packing and temporary abdominal closure, ICU restoration of normal physiology, and delayed definitive repair of intra-abdominal injuries. The decision for damage control should be made very early in the operation before the onset of severe coagulopathy, acidosis, and hypothermia. Early institution of packing as a damage control technique has been shown to lessen mortality.<sup>28–30</sup> Close observation in the ICU for continued bleeding is warranted as is monitoring for abdominal compartment syndrome. A recent prospective study has demonstrated that the early use of open abdomens in patients at risk for intra-abdominal hypertension/abdominal compartment syndrome enhanced survival.<sup>31</sup> Frequent monitoring of bladder pressures is warranted.<sup>31,32</sup>

Postoperative angiography has been recommended by some authors after damage control laparotomy.<sup>33,34</sup> Badellino and coworkers<sup>33</sup> reported that 52% of patients demonstrated bleeding on postoperative hepatic angiography. Similarly, in a study by Schwab and coworkers,<sup>34</sup> half of patients with perihepatic packing and damage control underwent angiography and 62% of these demonstrated active bleeding. However, not all studies have reported such high therapeutic rates for embolization.<sup>35</sup> At the current time, the specific subset of patients who would benefit most from hepatic angiography is not well defined. Prospective studies are needed before definitive recommendations. Complications have been reported in more than 40% of patients after angioembolization and include parenchymal necrosis, bile leak, abscess, and liver failure.<sup>35,36</sup>

- D. Bleeding not controlled by packing alone suggests a complex hepatic injury. An orderly assessment of the injury should be undertaken.<sup>37,38</sup> The first step entails a Pringle maneuver, with placement of a vascular clamp on the porta hepatis to control portal vein and hepatic artery bleeding. If not already performed, takedown of the falciform, coronary, and triangular ligaments should be undertaken.
- E. Once bleeding is controlled by the Pringle, actively bleeding vessels and injured bile ducts should be ligated. Although not performed as often with the increased use of packing, finger fracture of the hepatic parenchyma can aid in this endeavor. Placement of deep parenchymal sutures to obtain hemostasis is also an option, although there is a risk of tissue necrosis or injury to intact vessels and bile ducts.<sup>39</sup> For hepatic parenchymal devascularization or destruction, resectional debridement along nonsegmental planes should be performed. The need for formal resection is rare, especially at the time of initial surgery. Perhaps Dr. Mays best described the indication for formal resection in his 1979 report: “major resection should be done only when an entire lobe of the liver is reduced to pulp.”<sup>40</sup> Placement of a viable piece of omentum can fill in dead space and aid in hemostasis.<sup>37</sup> Pachter et al.<sup>14,37</sup> reported

successful management of grade III and IV injuries by a combination of portal triad occlusion, finger fracture, and omental pack.

- F. If bleeding persists despite the above maneuvers, selective hepatic artery ligation can be considered by those experienced in the procedure.<sup>11</sup> This maneuver poses a risk of liver necrosis, particularly when accompanied by deep liver sutures or overzealous packing. It should therefore be performed judiciously.<sup>40,41</sup> Postoperative angioembolization is a better option when possible.
- G. If significant bleeding persists after a Pringle maneuver, juxtahepatic venous injury to the retrohepatic vena cava or major hepatic veins must be suspected. Every effort should be made to control bleeding by packing. Buckman et al.<sup>42</sup> make a strong argument against any type of direct repair, citing evidence of improved mortality by omental and/or gauze packing. If significant bleeding refractory to packing mandates further operative intervention at the time of initial laparotomy, mortality is high irrespective of approach. Dismal results with direct repair alone led to the introduction of vascular isolation with shunting. Isolation entails control of the hepatic artery and portal vein by a Pringle maneuver, control of the subhepatic, suprarenal cava, and control of the suprahepatic cava. The atriocaval shunt was introduced by Schrock et al.<sup>12</sup> but has largely been abandoned due to high associated mortality except in the hands of surgeons experienced in its placement. Newer strategies of vascular isolation such as venovenobypass can be useful if available and performed before significant shock, hypothermia, and coagulopathy.<sup>43</sup> This procedure entails vascular isolation along with establishment of femoral to axillary or jugular venovenobypass. It can also be used at the time of delayed laparotomy for patients who initially respond to packing. Finally, there are several case reports on the use of fenestrated stent grafts by surgeons familiar with their use.<sup>44–46</sup>
- H. The precise timing of delayed laparotomy is not well defined, but should occur after the patient has been adequately resuscitated to include correction of hypothermia, acidosis, and coagulopathy. This is the time to remove packs and reevaluate the injured liver. Once packs are removed, assess for ongoing bleeding, biliary leak, and associated nonhepatic injuries. If nonviable parenchyma is noted, local resection is frequently all that is required. Formal resection, although commonly practiced in the past, is rarely indicated. University of Pittsburgh recently reported the safety of hepatic resection in the management of complex liver injuries.<sup>47</sup> Reasons cited for resection included bleeding/vascular injury, parenchyma disruption, necrotic tissue, and intraparenchymal bile leak. Their excellent results suggest that delayed resection may be an option in select cases at institutions with the appropriate expertise.

A Cochrane Review examining the use of routine drainage for uncomplicated liver resections concluded that there is no evidence to support routine drainage.<sup>48</sup> For trauma, studies have clearly demonstrated that the use of

closed suction drainage is superior to open drainage and routine drainage is not warranted.<sup>49,50</sup> In general, a drain should be considered when there is a suspected bile leak at the time of laparotomy, although this has not been well investigated.<sup>51</sup> With perihilar injuries associated with large bile leaks, cholangiography can help identify injured ducts that are surgically accessible. Most cases of postoperative bile leaks or perihepatic abscesses (with or without placement of an operatively placed drain) can be successfully treated by percutaneous techniques.<sup>52</sup> The majority of peripheral biliary leaks will seal without treatment, and continued high-output biliary drainage may warrant adjunctive endoscopic retrograde cholangiopancreatography and stenting. A multidisciplinary approach is useful in the management of postoperative hepatic complications and is discussed in the nonoperative blunt hepatic algorithm.<sup>53</sup>

### REFERENCES

- McIntyre RC, Moore FA, Davis JW, Cocanour CS, West MA, Moore EE Jr. Western Trauma Association critical decisions in trauma: foreword. *J Trauma*. 2008;65:1005–1006.
- Lucas CE, Ledgerwood AM. The academic challenge of teaching psychomotor skills for hemostasis of solid organ injury. *J Trauma*. 2009;66:636–640.
- Lee SK, Carrillo EH. Advances and changes in the management of liver injuries. *Am Surg*. 2007;73:201–206.
- Richardson JD. Changes in the management of injuries to the liver and spleen. *J Am Coll Surg*. 2005;200:648–669.
- Tinkoff G, Esposito T, Reed J, et al. American Association for the Surgery of Trauma Organ Injury Scale I: spleen, liver, and kidney, validation based on the National Trauma Data Bank. *J Am Coll Surg*. 2008;207:646–655.
- Pringle JH. Notes on the arrest of hepatic hemorrhage due to trauma. *Ann Surg*. 1908;48:541–548.
- Madding GF, Lawrence KB, Kennedy PA. Forward surgery of the severely wounded. *Second Auxiliary Surgical Group* 1945;1:307.
- Madding GF, Lawrence KB, Kennedy PA. Forward surgery of the severely wounded. *US Army Bull*. 1946;5:579.
- Madding GF. Injuries of the liver. *Arch Surg*. 1955;70:748–756.
- McClelland R, Shires T, Poulos E. Hepatic resection for massive trauma. *J Trauma* 1964;4:282–291.
- Aaron S, Fulton RL, Mays ET. Selective ligation of the hepatic artery for trauma of the liver. *Surg Gynecol Obstet*. 1975;141:187–189.
- Schrock T, Blaisdell FW, Mathewson C Jr. Management of blunt trauma to the liver and hepatic veins. *Arch Surg*. 1968;96:698–704.
- Lin TY. A simplified technique for hepatic resection: the crush method. *Ann Surg*. 1974;180:285–290.
- Pachter HL, Spencer FC. Recent concepts in the treatment of hepatic trauma: facts and fallacies. *Ann Surg*. 1979;190:423–429.
- Stone HH, Lamb JM. Use of pedicled omentum as an autogenous pack for control of hemorrhage in major injuries of the liver. *Surg Gynecol Obstet*. 1975;141:92–94.
- Lucas CE, Ledgerwood AM. Prospective evaluation of hemostatic techniques for liver injuries. *J Trauma*. 1976;16:442–451.
- Calne RY, McMaster P, Pentlow BD. The treatment of major liver trauma by primary packing with transfer of patient for definitive treatment. *Br J Surg*. 1979;66:338–339.
- Feliciano DV, Mattox KL, Jordan GL Jr. Intra-abdominal packing for control of hepatic hemorrhage: a reappraisal. *J Trauma*. 1981;21:285–290.
- Elerding SC, Arragon GE, Moore EE. Fatal hepatic hemorrhage after trauma. *Am J Surg* 1979;138:883–888.
- Kashuk JL, Moore EE, Millikan JS, Moore JB. Major abdominal vascular trauma—a unified approach. *J Trauma*. 1982;22:672–679.
- Stone HH, Strom PR, Mullins RJ. Management of the major coagulopathy with onset during laparotomy. *Ann Surg*. 1983;197:532–535.
- Burch JM, Ortiz VB, Richardson RJ, Martin RR, Mattox KL, Jordan GL. Abbreviated laparotomy and planned reoperation for critically injured patients. *Ann Surg*. 1992;215:476–483.
- Cotton BA, Gunter OL, Isbell J, et al. Damage control hematology: the impact of a trauma exsanguination protocol on survival and blood product utilization. *J Trauma*. 2008;64:1177–1182.
- Sihler KC, Napolitano LM. Complications of massive transfusion. *Chest*. 2010;137:209–220.
- Ramkumar K, Perera MT, Marudanayagam R, et al. A reaudit of specialist-managed liver trauma after establishment of regional referral and management guidelines. *J Trauma*. 2010;68:84–89.
- Demetriades D. Balloon tamponade for bleeding control in penetrating liver injuries. *J Trauma*. 1998;44:538–539.
- Rotondo MF, Schwab CW, McGonigal MD, et al. ‘Damage control’: an approach for improved survival in exsanguinating penetrating abdominal injury. *J Trauma*. 1993;35:375–383.
- Asensio JA, Roldan G, Petrone P, et al. Operative management and outcomes in 103 AAST-OIS grades IV and V complex hepatic injuries: trauma surgeons still need to operate, but angioembolization helps. *J Trauma*. 2003;54:647–654.
- Feliciano DV, Mattox KL, Burch JM, Bitondo CG, Jordan GL Jr. Packing for control of hepatic hemorrhage. *J Trauma*. 1986;26:738–743.
- Cogbill TH, Moore EE, Jurkovich GJ, Feliciano DV, Morris JA, Mucha P. Severe hepatic trauma: a multicenter experience with 1,335 liver injuries. *J Trauma*. 1088;28:20:438–444.
- Cheatham ML, Safcsak K. Is the evolving management of intra-abdominal hypertension and abdominal compartment syndrome improving survival? *Crit Care Med*. 2010;38:402–407.
- Cheatham ML, Malbrain ML, Kirkpatrick A, et al. Results from the International Conference of Experts on Intra-abdominal Hypertension and Abdominal Compartment Syndrome. II. Recommendations. *Intensive Care Med*. 2007;33:951–962.
- Misselbeck TS, Teicher E, Cipolle M, et al. Hepatic angioembolization in trauma patients: indications and complications. *J Trauma*. 2009;67:769–773.
- Johnson JW, Gracias VH, Gupta R, et al. Hepatic angiography in patients undergoing damage control laparotomy. *J Trauma*. 2002;52:1102–1106.
- Dabbs DN, Stein DM, Scalea TM. Major hepatic necrosis: a common complication after angioembolization for treatment of high-grade injuries. *J Trauma*. 2009;66:621–627.
- Mohr AM, Lavery RF, Barone A, et al. Angiographic embolization for liver injuries: low mortality, high morbidity. *J Trauma*. 2003;55:1077–1082.
- Pachter HL, Spencer FC, Hofstetter SR, Liang HG, Coppa GF. Significant trends in the management of hepatic trauma. Experience with 411 injuries. *Ann Surg*. 1992;215:492–500.
- Pachter HL, Feliciano DV. Complex hepatic injuries. *Surg Clin North Am*. 1996;76:763–782.
- Feliciano DV, Mattox KL, Jordan GL, Burch JM, Bitondo CG, Cruse PA. Management of 1000 cases of hepatic trauma (1979–1984). *Ann Surg*. 1986;204:438–445.
- Mays ET, Conti S, Fallahzadeh H, Rosenblatt M. Hepatic artery ligation. *Surgery*. 1979;86:536–543.
- Lucas CE, Ledgerwood AM. Liver necrosis following hepatic artery transection due to trauma. *Arch Surg*. 1978;113:1107.
- Buckman RF, Miraliakbari R, Badellino MM. Juxtahepatic venous injuries: a critical review of reported management strategies. *J Trauma*. 2000;48:978–984.
- Baumgartner F, Scudamore C, Nair C, Karusseit O, Hemming A. Venovenobypass for major hepatic and caval trauma. *J Trauma*. 1995;39:671–673.
- Sam AD, Frusha JD, McNeil JW, Olinde AJ. Repair of a blunt traumatic inferior vena cava laceration with commercially available endografts. *J Vasc Surg*. 2006;43:841–843.
- Emergency endovascular repair for traumatic injury of the inferior vena cava. *Eur J Cardiothorac Surg*. 2005;28:906–908.
- Erzurum VZ, Shoup M, Borge M, Kalman PG, Rodriguez H, Silver GM. Inferior vena cava endograft to control surgically inaccessible hemorrhage. *J Vasc Surg*. 2003;38:1437–1439.
- Polanco P, Leon S, Pineda J, et al. Hepatic resection in the management of complex injury to the liver. *J Trauma*. 2008;65:1264–1270.

48. Gurusamy KS, Samraj K, Davidson BR. Routine drainage for uncomplicated liver resection. *Cochrane Database Syst Rev.* 2007;(3):CD006232.
49. Noyes LD, Doyle DJ, McSwain NE. Septic complications associated with the use of peritoneal drains in liver trauma. *J Trauma.* 1988;28:337–346.
50. Fabian TG, Croce MA, Stanford GG, et al. Factors affecting morbidity following hepatic trauma. A prospective analysis of 482 injuries. *Ann Surg* 1991;213:540–547.
51. Mullins RJ, Stone HH, Dunlop WE, Strom PR. Hepatic trauma: evaluation of routine drainage. *South Med J.* 1985;78:259–261.
52. Kozar RA, Moore JB, Niles SE, et al. Complications of nonoperative management of high-grade blunt hepatic injuries. *J Trauma.* 2005;59:1066–1071.
53. Kozar RA, Moore FA, Moore EE, et al. Western Trauma Association critical decisions in trauma: nonoperative management of adult blunt hepatic trauma. *J Trauma.* 2009;67:1144–1148.

#### G. WHITAKER INTERNATIONAL BURNS PRIZE FOR 2011

The 2011 G. Whitaker International Burns Prize in burn medicine has been awarded to Dr. A. Elizabeth van der Merwe, head of the Tygerberg Burn Unit, Tygerberg Hospital, Cape Town South Africa. Dr. van der Merwe studied at the University of Stellenbosch where she received her MD degree in 1972. Dr. van der Merwe established a course of study on Emergency Burns Management which is now a compulsory course in the South African physician-in-training academic curriculum. Dr. van der Merwe will be awarded the G. Whitaker International Burns Prize on September 23, 2011 in Palermo, Italy.

Nominations for the 2013 prize are being accepted until January 31, 2013. Send a detailed curriculum vitae to: Michele Masellis M.D., Secretary-Member of the Scientific Committee, G. Whitaker Foundation, Via Dante 167, 90141 Palermo, Italy.