



CLINICAL/ORIGINAL PAPERS

Regional right ventricular dysfunction in acute pulmonary embolism and right ventricular infarction

Franco Casazza*, Amedeo Bongarzoni, Angela Capozzi, Ornella Agostoni

Division of Cardiology, San Carlo Borromeo Hospital, via Pio 2°, n 3, 20153 Milan, Italy

Received 14 April 2004; received in revised form 14 April 2004; accepted 2 June 2004

KEYWORDS

Echocardiography;
Right ventricular wall
motion;
Pulmonary embolism;
Right ventricular
infarction

Abstract Background A normally contracting right ventricular apex associated to a severe hypokinesia of the mid-free wall ('McConnell sign') has been considered a distinct echocardiographic pattern of acute pulmonary embolism.

Objective To evaluate the clinical utility of the 'McConnell sign' in the bedside diagnostic work-up of patients presenting to the Emergency Department with an acute right ventricular dysfunction due to pulmonary embolism or right ventricular infarction.

Design Among 201 patients, consecutively selected from our clinical database and diagnosed as having massive or submassive pulmonary embolism or right ventricular infarction, 161 were suitable for an echocardiographic review of regional right ventricular contraction and were included in the study. There were 107 cases with pulmonary embolism (group 1) and 54 cases with right ventricular infarction (group 2). All echocardiographic studies were randomly examined by two experienced and independent echocardiographers, blinded to the patient diagnosis and without Doppler informations.

Results The McConnell sign was detected in 75 of 107 patients in group 1 (70%) and in 36 of 54 patients in group 2 (67%); the finding was absent in 32 cases in group 1 and in 18 cases in group 2 ($P = 0.657$). The sensitivity, specificity, positive and negative predictive values of the McConnell sign for the diagnosis of pulmonary embolism were respectively 70, 33, 67 and 36%.

Conclusions In a clinical setting of patients with acute right ventricular dysfunction the McConnell sign cannot be considered a specific marker of pulmonary embolism.

© 2004 The European Society of Cardiology. Published by Elsevier Ltd. All rights reserved.

* Corresponding author. via Nikolajevka 12, 20152, Milan, Italy. Tel.: +39-2-4022-2943.
E-mail address: fcasazza@tin.it (F. Casazza).

Introduction

Echocardiography is recognized as an important tool in the rapid diagnostic work-up and in prognostic stratification of pulmonary embolism (PE).^{1–6} In association with a high or intermediate clinical probability, the findings of right ventricular (RV) dysfunction and pulmonary hypertension are crucial in increasing the clinical suspicion of PE and in initiating the appropriate therapy, including thrombolysis in unstable cases.^{7,8} Echocardiographic approach is especially worthwhile in the Emergency Department or Coronary Care Unit to investigate patients with circulatory failure of uncertain cause, when the electrocardiogram is not conclusive.

In 1996, by means of quantitative and qualitative analyses, McConnell et al. described in pulmonary embolism a 'distinct echocardiographic pattern of RV dysfunction', characterized by a severe hypokinesia of RV mid-free wall, with a normal contraction of the apical segment⁹ (Fig. 1a,b). In comparison with several conditions involving the RV, the finding showed a 77% sensitivity and a 94% specificity, with a positive and negative predictive values of 71 and 96%, respectively. The authors therefore suggested that the presence of this echocardiographic sign should raise the level of clinical suspicion for the diagnosis of PE and prompt further diagnostic evaluation. To the best of our knowledge, no other study has been carried out to confirm these single observations; yet this abnormality has become widely known as the 'McConnell sign' and holds a position in the scenario of 2D echocardiographic hallmarks of PE.^{10,11} The aim of the present study was to evaluate the diagnostic yield of the 'McConnell sign' in patients exclusively affected by an acute RV dysfunction.

Methods

A total of 201 patients with massive or submassive PE¹² or a first RV infarction were consecutively selected from our clinical database between January 1998 and May 2003. The echocardiographic recordings, obtained within 24 h of admission (mainly within 2 h), were initially reviewed by one of us in order to select appropriate views from videotapes for a subsequent blind evaluation. Forty cases were excluded due to: poor quality images in 20 cases, absence of a clear RV hypokinesia in 12 cases with RV infarction, free floating right heart thrombi in nine cases. A total of 161 patients were therefore included in this

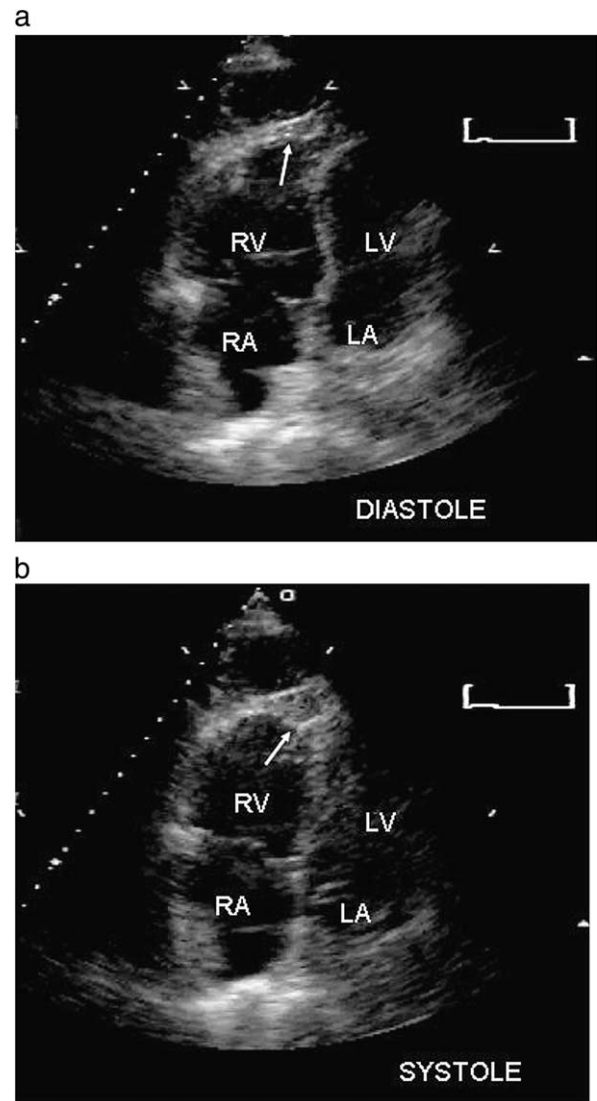


Figure 1 Echocardiographic 4-chamber views of a patient with massive pulmonary embolism and right ventricular dysfunction in end-diastole (a); and in end-systole (b). Arrows indicate normally contracting apical segments in a globally hypokinetic right ventricle (McConnell sign). RV, right ventricle; RA, right atrium; LV, left ventricle; and LA, left atrium.

retrospective study: 107 cases with PE, all confirmed by spiral CT (group 1) and 54 cases with RV infarction, confirmed by ST-segment elevation ≥ 1 mm in lead V_{4r} (group 2). No patient in group 2 had known arterial or venous pulmonary hypertension. In group 1, there were 44 males and 63 females with a mean age of 68.4 ± 23 years (range 24–88 years); in group 2 there were 32 males and 22 females with a mean age of 69.2 ± 10 years (range 48–95 years).

Echocardiograms were randomly evaluated by two experienced and independent echocardiographers, blinded to the patient diagnosis and without

Doppler informations. A qualitative wall motion analysis of the presence or absence of the McConnell sign was performed in the apical four-chamber view for ≥ 3 cardiac cycles and discrepancies were resolved by consensus. Interobserver agreement was 89%. For categorical variables, the comparison between the two groups was performed with chi square test.

Results

A pattern of normal wall motion of the apex and abnormal wall motion in the mid-free wall of the right ventricle was detected in 75 of 107 patients (70%) in group 1 and in 36 of 54 patients (67%) in group 2; the finding was absent in 32 cases in group 1 and in 18 cases in group 2 (Table 1). The sensitivity, specificity, positive and negative predictive values of the McConnell sign for the diagnosis of pulmonary embolism were respectively 70, 33, 67 and 36%.

Discussion

Pulmonary embolism and RV infarction may present with similar clinical and electrocardiographic findings: chest pain, sweating, hypotension or shock, ST-segment elevation and/or q waves in inferior leads or in V_1 . In both diseases 2D-echo may show enlargement of right heart chambers, right ventricular hypokinesia, iv septal dyskinesia and inferior vena cava dilation, while ischemic left ventricular inferior wall abnormalities may be subtle when infarction predominantly involves the right ventricle. CW Doppler helps differentiate the two conditions by demonstration of an increased RV-RA pressure gradient in massive or submassive PE, and of a normal or low gradient in RV infarction. In these sometimes confounding conditions,

a new echocardiographic pattern of RV contraction, highly specific for the diagnosis of PE, would be very useful, especially in cases of trivial tricuspid insufficiency and/or difficult estimation of velocities and gradients across the tricuspid valve. Unfortunately the results of our study show that the McConnell sign is unable to differentiate acute PE from RV infarction. Actually, this sign was present in 70% of PE and in 67% of RV infarctions, with a very low specificity and negative predictive value. The presence or the absence of the sign cannot therefore confirm or exclude the diagnosis of PE. Indeed our data are at variance with those of McConnell et al.,⁹ who compared a small group of PE patients with a very heterogeneous population of 85 patients collected on the basis of the presence of echocardiographic signs of RV dysfunction. Causes of RV dysfunction were mainly chronic diseases such as ischemic or dilated cardiomyopathies ($n = 30$), chronic pulmonary hypertension ($n = 11$), valvular heart disease ($n = 9$), congenital heart disease ($n = 7$). Just seven cases of acute RV dysfunction were included, namely six RV infarctions and one acute respiratory distress syndrome. Since the sole false positive case, incidentally quoted in the paper, was the only one suffering from the acute respiratory distress syndrome, the authors stated that 'patients with other causes of an acute increase in RV afterload may have similar findings'. The results of the present study demonstrate that not only causes of acute increase in RV afterload other than PE may show similar findings, but also diseases directly involving the right ventricle, such as RV infarction, may also account for the onset of the McConnell sign. We are therefore still looking for a specific echocardiographic pattern of acute PE.

Three mechanisms were advocated by McConnell⁹ to explain the pathogenesis of their findings in pulmonary embolism: tethering of the RV apex to a contracting hyperdynamic left ventricle, a systolic bulging localized to the mid-free wall due to an abrupt increase in afterload which spares the apex and, third, a segmental ischemia of the RV free wall. According to our observations, the first two mechanisms seem quite unlikely because: (1) the RV apex motion is a real inward movement and not just a tethering; and (2) in RV infarction a sudden increase in afterload does not develop in spite of the presence of a normal contracting apex in 67% of our cases. We therefore believe that the most consistent mechanism to explain the McConnell sign could be ischemia: a functional ischemia of the RV free wall in PE, due to a transient increase in wall stress, and a necrotic involvement of the RV free wall in RV infarction, due to

Table 1 Prevalence of McConnell sign in patients with acute PE and RV infarction

	Pulmonary Embolism N° (%)	RV infarction N° (%)	Patients N° (%)
McConnell sign present	75 (70%)	36 (67%)	111 (69%)
McConnell sign absent	32 (30%)	18 (33%)	50 (31%)
Total	107 (100%)	54 (100%)	161 (100%)

Chi-square statistic: $\chi^2 = 0.197$ ($P = 0.657$).

mechanical obstruction of the right coronary artery. Yet, the exact reason why the apex is the sole normally contracting segment in an otherwise hypokinetic right ventricle both in acute PE and RV infarction remains still unclear.

In conclusion, the present study confirms the fairly good sensibility but not the high specificity of the McConnell sign for the echocardiographic diagnosis of acute pulmonary embolism, since a normal contracting RV apex could be detected also in two thirds of patients with RV infarction. This regional pattern of RV contraction cannot therefore be used in the bedside diagnostic work-up of critically ill patients with acute right ventricular dysfunction to raise the clinical suspicion of acute cor pulmonale.

References

1. Kasper W, Meinertz T, Henkel B, Eissner D, Hahn K, Hofmann T, et al. Echocardiographic findings in patients with proven pulmonary embolism. *Am Heart J* 1986;**112**:1284–90.
2. Torbicki A, Tramarin R, Morpurgo M. Role of echo/Doppler in the diagnosis of pulmonary embolism. *Clin Cardiol* 1992;**15**: 805–10.
3. Nazeyrollas P, Metz D, Jolly D, Maillier B, Jenneaux C, Maes D, et al. Use of transthoracic Doppler echocardiography combined with clinical and electrocardiographic data to predict acute pulmonary embolism. *Eur Heart J* 1996;**17**: 779–86.
4. Jardin F, Dubourg O, Boundarias JP. Echocardiographic pattern of acute cor pulmonale. *Chest* 1997;**111**:1209–17.
5. Goldhaber SZ, Visani L, De Rosa M. Acute pulmonary embolism: clinical outcomes in the International Cooperative registry (ICOPER). *Lancet* 1999;**353**:1386–9.
6. Grifoni S, Olivetto I, Cecchini P, Pieralli F, Camaiti A, Santoro F, et al. Short-term clinical outcome of patients with acute pulmonary embolism, normal blood pressure and echocardiographic right ventricular dysfunction. *Circulation* 2000;**101**:2817–22.
7. Cheriex EC, Sreeram N, Eussen YFJM, Pieters FAA, Wellens HJJ. Cross sectional Doppler echocardiography as the initial technique for the diagnosis of acute pulmonary embolism. *Br Heart J* 1994;**72**:52–7.
8. Kasper W, Konstantinides S, Geibel A, Olschewski M, Heinrich F, Grossner KD. Management strategies and determinants of outcome in acute major pulmonary embolism: results of a multicenter registry. *J Am Coll Cardiol* 1997;**30**:1165–71.
9. McConnell MV, Solomon SD, Rayan ME, Come PC, Goldhaber SZ, Lee RT. Regional right ventricular dysfunction detected by echocardiography in acute pulmonary embolism. *Am J Cardiol* 1996;**78**:469–73.
10. Goldhaber SZ. Echocardiography in the management of pulmonary embolism. *Ann Intern Med* 2002;**136**:691–700.
11. Wood KE. Major pulmonary embolism. Review of a pathophysiologic approach to the golden hour of hemodynamically significant pulmonary embolism. *Chest* 2002;**121**:877–905.
12. Task Force on Pulmonary Embolism. European Society of Cardiology. Guidelines on diagnosis and management of acute pulmonary embolism. *Eur Heart J* 2000;**21**:1301–36.