

Commentary and concepts

Point-of-care ultrasound evaluation of pericardial effusions: Does this patient have cardiac tamponade?☆

Arun Nagdev*, Michael B. Stone

Department of Emergency Medicine, Highland General Hospital, 1411 East 31st Street, Oakland, CA 94602, United States

ARTICLE INFO

Article history:

Received 28 July 2010

Received in revised form 23 January 2011

Accepted 3 February 2011

Keywords:

Echocardiography
Cardiac tamponade
Inferior vena cava

ABSTRACT

Detection of pericardial effusions using point-of-care focused echocardiography is becoming a common application for clinicians who care for critical patients. Identification of tamponade physiology is of great utility, as these patients require urgent evaluation and management. We describe techniques that the point-of-care clinician sonographer can use to determine the presence or absence of echocardiographic evidence of cardiac tamponade.

© 2011 Elsevier Ireland Ltd. All rights reserved.

1. Introduction

Evaluation of the patient in shock or pulseless electrical activity must include prompt recognition of reversible causes of hemodynamic instability. Among these, identification of cardiac tamponade is of particular importance as treatment is disease-specific, requiring emergent drainage of pericardial fluid. Unfortunately, detection of cardiac tamponade using classic physical exam signs such as Beck's triad of hypotension, distended neck veins and muffled heart sounds can be quite inaccurate.¹

Transthoracic echocardiography is the study of choice for the rapid and safe evaluation of pericardial effusions.² It is non-invasive, performed at the bedside, and has the distinct advantage of detecting evidence of impending cardiac tamponade in patients who have not yet developed hypotension. Classically, cardiac tamponade is defined as a condition in which the pericardial fluid impinges on cardiac function, decreasing cardiac output. Echocardiographic evaluation allows for detection of subclinical signs of cardiac dysfunction, allowing the clinician the ability to make the diagnosis much earlier on the continuum of disease.

Increasingly, clinicians at the patient's point-of-care (such as emergency physicians and intensivists) have adopted the use of focused point-of-care cardiac ultrasound (PCU) to aid in the evaluation of the critically ill, and have demonstrated competency in basic cardiac evaluations such as detection of pericardial effusion

and assessment of global left ventricular function.^{3–5} Although clinicians may be able to accurately identify pericardial effusions, the majority of these effusions are not associated with tamponade physiology. Determination of the presence or absence of impending cardiac tamponade is therefore of considerable importance to clinicians caring for the normotensive patient with a pericardial effusion.

Echocardiographic evidence of cardiac tamponade is characterized by (1) diastolic collapse of the right ventricle and right atrium, (2) exaggerated respiratory variations of transmitral and transtricuspid Doppler inflow velocities, and (3) inferior vena cava (IVC) plethora.^{6–9} These findings will be discussed as they apply to the point-of-care clinician-sonographer who wishes to determine if echocardiographic evidence of tamponade exists.

2. Point-of-care cardiac ultrasound (PCU) for tamponade

2.1. Chamber collapse

Diastolic collapse of the cardiac chambers (particularly the right ventricle and right atrium) is the most commonly cited criteria for echocardiographic confirmation of tamponade physiology.¹⁰ Clinicians who perform PCU, however, have traditionally been at a considerable disadvantage when attempting to determine if diastolic chamber collapse exists. Comprehensive (consultative) transthoracic echocardiography is performed with real-time ECG monitoring which correlates echocardiographic findings with the phase of the cardiac cycle. Therefore, diastolic versus systolic chamber collapse is easily differentiated. PCU is often performed without real-time ECG monitoring, and clinicians may not be able

☆ A Spanish translated version of the abstract of this article appears as Appendix in the final online version at [doi:10.1016/j.resuscitation.2011.02.004](https://doi.org/10.1016/j.resuscitation.2011.02.004).

* Corresponding author. Tel.: +1 401 623 9106.

E-mail address: arunnagdev@gmail.com (A. Nagdev).

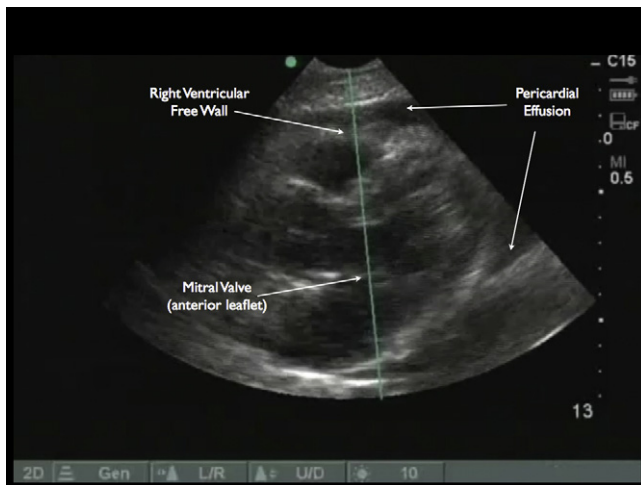


Fig. 1. Parasternal long image using radiology orientation.

to easily identify a given phase of the cardiac cycle, especially in the presence of marked tachycardia: providers may be unable to differentiate systolic (physiologic) from diastolic (pathologic) collapse.

While right atrial collapse may be the earliest indicator of tamponade, it is a nonspecific finding that may be associated with other common condition is emergency department patients such as pleural effusions or severe dehydration. Diastolic collapse of the right ventricle can readily be identified, however, using a technique that does not require ECG monitoring¹¹; utilizing M-mode (motion mode), commonly available on inexpensive portable ultrasound systems. Via a longitudinal image of the heart, from the parasternal or subcostal window, an M-mode view that incorporates the right ventricular free wall and the mitral valve is obtained (Fig. 1). Diastole is easily identified as the period from mitral valve opening to mitral valve closure. In cardiac tamponade, compression of the right ventricular free wall begins as the mitral valve opens in early diastole. Posterior motion of the right ventricular free wall at any point during diastole (from opening to the closing of the mitral valve) is abnormal and indicates diastolic collapse. Right ventricular free wall motion is therefore easily compared to the cardiac cycle, enabling accurate identification of diastolic chamber collapse without the need for ECG monitoring (Fig. 2). An alternative technique involves freezing the screen and manually scrolling frame by frame through the cardiac cycle to determine the timing of right ventricular collapse.

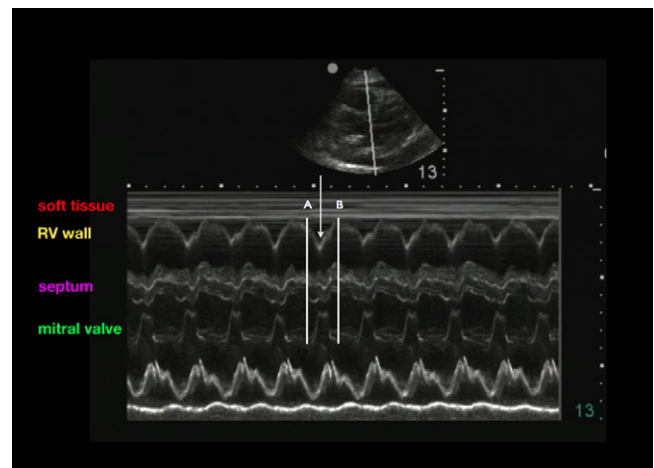


Fig. 2. M-mode image obtained from parasternal long orientation. Diastole, with associated mitral valve opening and right ventricular free wall collapse, occurs between the A and B. The arrow represents the abnormal posterior wall motion of the right ventricular free wall in early diastole.

2.2. Transvalvular Doppler inflow

Exaggerated respiratory variations in transmitral and transtricuspid Doppler inflow, known as flow velocity paradoxus, can also accurately identify the presence of tamponade physiology. However, in contrast to PCU evaluation of chamber collapse, estimation of transvalvular flow velocities requires considerable additional skill. Image acquisition can be more challenging: in contrast to the parasternal and subcostal views needed to assess chamber collapse, atrio-ventricular valve Doppler inflow velocities are best estimated from an apical view (which is often the most challenging to obtain). In addition, a thorough understanding of Doppler principles and the ability to adjust multiple parameters on the ultrasound system is required to accurately measure transvalvular Doppler inflow. In tachycardic patients, differentiation of A and E waves can be challenging, even in experienced hands. For all of these reasons, estimation of transvalvular Doppler inflow velocities is unlikely to be of great benefit to the majority of point-of-care clinician-sonographers.

2.3. Inferior vena cava (IVC) plethora

Clinician-sonographers can accurately determine the degree of inferior vena cava (IVC) collapse using PCU.^{12–14} As pericardial pressures impede venous return and IVC pressures increase, the normal respiro-phasic property of the IVC is diminished: despite changes in

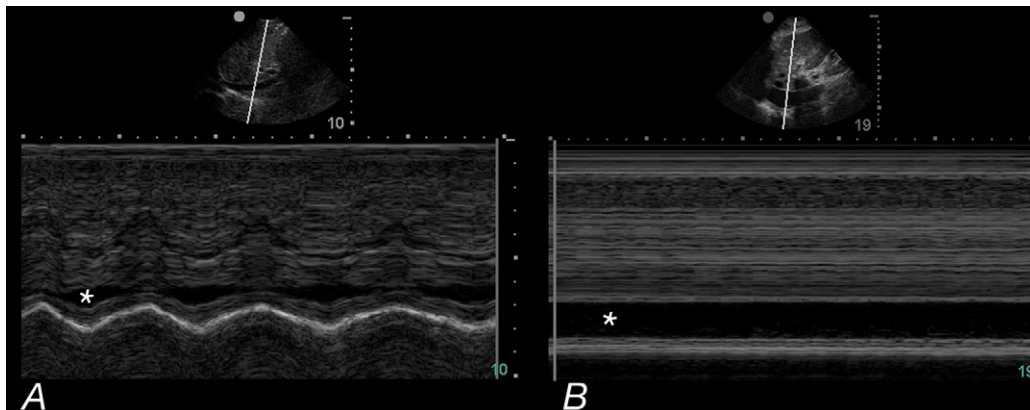


Fig. 3. (A) Normal respirophasic collapse of the IVC (*); (B) plethoric IVC (*) in a patient with cardiac tamponade.

intra-thoracic pressure, the IVC remains plethoric throughout the respiratory cycle. In normal patients, the IVC collapses to varying degree based on hydration status or underlying cardiopulmonary disease. Failure of the IVC to noticeably collapse during spontaneous respiration may indicate elevated right-sided pressures due to volume overload, pulmonary embolism, valvular disease or cardiac tamponade. This can be visualized using real-time B-mode sonography, or with the use of M-mode (Fig. 3).

2.4. Limitations of echocardiography

Although cardiac tamponade may be diagnosed using the findings discussed, point-of-care clinician-sonographers need be aware that the echocardiographic examination has limitations. For example, conditions such as severe hypovolemia or large pleural effusions can cause diastolic chamber collapse. In addition, disease states that increase right-sided cardiac pressures (pulmonary hypertension, etc.) may prevent diastolic chamber collapse. If a patient with a pericardial effusion demonstrates clinical signs of shock, cardiac tamponade should be considered as a possible cause, regardless of chamber collapse, transvalvular Doppler inflow, or IVC dynamics.

3. Discussion

Rapid diagnosis and intervention in patients with cardiac tamponade is an essential skill in emergency and critical care medicine. While transthoracic “B mode” (grayscale) sonography can reliably detect pericardial effusions, it does not reliably allow determination of hemodynamic compromise: patients with large effusions may not experience hemodynamic instability, and those with small pericardial effusions may experience cardiac tamponade.¹⁵ Comprehensive echocardiography is performed using attached electrocardiographic (ECG) leads which identify the phase of the cardiac cycle in which the cardiac chambers collapse. Early right ventricular collapse in diastole is commonly accepted as evidence of impending tamponade, and informs the clinician’s approach to further management strategies.

Point-of-care ultrasonography is almost always performed without continuous ECG monitoring, forcing the clinician to use other methods to determine the presence of impending tamponade. Visualization of right ventricular free wall collapse during early diastole can be performed using M-mode¹⁶ (which is a common feature of point-of-care ultrasound systems), and clearly defines the presence of tamponade physiology. Inferior vena cava plethora can be identified using M-mode, or simply by observing the IVC during the respiratory cycle using standard B-mode (grayscale) imaging.

4. Conclusion

Clinicians who detect the presence of a pericardial effusion in patients without clinical evidence of shock should proceed directly

to further evaluate the movement of the right ventricular free wall and the respirophasicity of the inferior vena cava: this may allow for early diagnosis and management of cardiac tamponade before the development of hemodynamic collapse. As always, ultrasound findings must be interpreted in context of the overall clinical picture, and in patients with suspected tamponade, consultation with cardiology is recommended when available.

Conflict of interest statement

The authors have no commercial associations or sources of support that might pose a conflict of interest. The authors have no financial support in writing the manuscript, and have no financial interest associated with the manuscript.

References

- Jacob S, Sebastian JC, Cherian PK, et al. Pericardial effusion impending tamponade: a look beyond Beck’s triad. *Am J Emerg Med* 2009;27:216–9.
- Levine MJ, Lorell BH, Diver DJ, et al. Implications of echocardiographically assisted diagnosis of pericardial tamponade in contemporary medical patients: detection before hemodynamic embarrassment. *J Am Coll Cardiol* 1991;17:59–65.
- Mandavia DP, Hoffner RJ, Mahaney K, et al. Bedside echocardiography by emergency physicians. *Ann Emerg Med* 2001;38:377–82.
- Blaivas M. Incidence of pericardial effusion in patients presenting to the emergency department with unexplained dyspnea. *Acad Emerg Med* 2001;8:1143–6.
- Melamed R, Sprenkle MD, Ulstad VK, et al. Assessment of left ventricular function by intensivists using hand-held echocardiography. *Chest* 2009;135:1416–20.
- Troughton RW, Asher CR, Klein AL. Pericarditis. *Lancet* 2004;363:717–27.
- Appleton CP, Hatle LK, Popp RL. Cardiac tamponade and pericardial effusion: respiratory variation in transvalvular flow velocities studied by Doppler echocardiography. *J Am Coll Cardiol* 1988;11:1020–30.
- Himelman RB, Kircher B, Rockey DC, et al. Inferior vena cava plethora with blunted respiratory response: a sensitive echocardiographic sign of cardiac tamponade. *J Am Coll Cardiol* 1988;12:1470–7.
- Leeman DE, Levine MJ, Come PC. Doppler echocardiography in cardiac tamponade: exaggerated respiratory variation in transvalvular blood flow velocity integrals. *J Am Coll Cardiol* 1988;11:572–8.
- Reydel B, Spodick DH. Frequency and significance of chamber collapses during cardiac tamponade. *Am Heart J* 1990;119:1160–3.
- Armstrong WF, Schilt BF, Helper DJ, et al. Diastolic collapse of the right ventricle with cardiac tamponade: an echocardiographic study. *Circulation* 1982;65:1491–6.
- Randazzo MR, Snoey ER, Levitt MA, et al. Accuracy of emergency physician assessment of left ventricular ejection fraction and central venous pressure using echocardiography. *Acad Emerg Med* 2003;10:973–7.
- Nagdev AD, Merchant RC, Tirado-Gonzalez A, et al. Emergency department bedside ultrasonographic measurement of the caval index for noninvasive determination of low central venous pressure. *Ann Emerg Med* 2010;55:290–5.
- Barbier C, Loubières Y, Schmit C, et al. Respiratory changes in inferior vena cava diameter are helpful in predicting fluid responsiveness in ventilated septic patients. *Intensive Care Med* 2004;30:1740–6.
- Saito Y, Donohue A, Attai S, et al. The syndrome of cardiac tamponade with “small” pericardial effusion. *Echocardiography* 2008;25:321–7.
- Armstrong WF, Ryan T. Feigenbaum’s echocardiography. seventh edition Lippincott Williams & Wilkins; 2009.