Journal of Intensive Care Medicine
http://jic.sagepub.com/

Tracheoarterial Fistula: An Unusual Complication of Tracheostomy

Oren P. Schaefer and Richard S. Irwin

J Intensive Care Med 1995 10: 64
DOI: 10.1177/088506669501000203

Tracheoarterial Fistula: An Unusual Complication of Tracheostomy

Oren P. Schaefer, MD, and Richard S. Irwin, MD

Schaefer OP, Irwin RS. Tracheoarterial fistula: an unusual complication of tracheostomy. J Intensive Care Med 1995;10:64–75.

The tracheoarterial fistula is an unusual but devastating complication of tracheostomy. It occurs with a frequency of approximately 0.7%, and it is uniformly fatal if not recognized and surgically corrected. Mucosal damage from the tracheal cannula, pressure necrosis from high cuff pressure, or mucosal trauma from an improperly positioned cannula tip results in erosion through the tracheal wall into the vascular structures that lie in the pretracheal space. Bleeding from this complication almost always occurs late (> 48 hours postprocedure). It is often preceded by sentinel hemoptysis. A paucity of signs and symptoms that precede or are associated with this complication require a high index of clinical suspicion to make the diagnosis. In addition to bleeding, other potential clues include a low-lying tracheostomy tube, pulsation of the tracheostomy tube, and the presence of infection, hypotension, malnutrition, and corticosteroid use. Unfortunately, there are no consistently useful diagnostic tools for tracheoarterial fistula. Fiberoptic bronchoscopy and angiography have been performed with mixed results. Should no other cause be found to explain the hemorrhage from or around the tracheostomy, or from disease distal to the primary carina, the patient must be taken to the operating room for a more definitive examination and possible vascular repair. Management is divided into acute stabilization and support, with protection of the airway and restoration of circulating blood volume, followed by definitive repair should the patient survive. Measures to prevent tracheal damage by the tracheostomy tube, such as proper surgical technique and proper inflation of the tracheostomy tube cuff, may go a long way to avoid this potentially lethal complication. Early consideration of this entity may be what saves the life of its victim.

From the Division of Pulmonary and Critical Care Medicine, University of Massachusetts Medical School, Worcester, MA.

Received Sept 8, 1993, and in revised form May 3, 1994. Accepted for publication May 5, 1994.

Address correspondence to Dr Schaefer, Pulmonary and Critical Care Medicine, University of Massachusetts Medical Center, 55 Lake Ave North, Worcester, MA 01655.

Dr Schaefer is the recipient of a Will Rogers Pulmonary Research Fellowship.

Overview

Tracheostomy, a procedure performed since antiquity [1,2], has significant benefits, but it also has potential complications. Among the more common complications is hemorrhage. Minor hemorrhage during or shortly after tracheostomy is a frequent complication; it occurs with a frequency of up to 37% [3–12]. It results from faulty hemostasis of veins, capillaries, and even minor arteries during surgery. Major or massive hemorrhage (a term commonly used, but not clearly defined) is most often fatal. Fortunately, it is rare, and it occurs with an overall frequency of 0.7% [13–18] (Table 1). Following tracheostomy, massive hemorrhage from and around the trachea is almost always due to erosion through the tracheal wall into a large artery. It is delayed in onset, and it almost always occurs more than 48 hours following surgery.

Körte [19], in 1878, was the first to report massive hemorrhage from a tracheostomy. It occurred in a young girl who had the procedure done for laryngeal diphtheria. Schlaepfer [20], the first to collect a series of such cases, reported the frequency of massive tracheal hemorrhage in Europe at the turn of the century; it ranged from 0.5 to 4.5%. The bleeding, however, was not necessarily related to the presence of a tracheal cannula. Hemorrhage presumably resulted in many cases from the rupture of an aneurysm that formed as a consequence of

Table 1. Massive Hemorrhage from Tracheoarterial Fistula

No. Patients[a]	No. TA Fistula (%)	Reference
51	2 (4.0)	[7]
688	4 (0.6)	[12]
794	5 (0.6)	[13]
428	2 (0.5)	[14]
294	1 (0.3)	[15]
256	5 (2.0)	[16]
212	0 (0.0)	[8]
124	0 (0.0)	[9]
389	4 (1.0)	[17]
1,501	10 (0.7)	[18]

[a]Data gathered from series of tracheotomized patients.
TA = tracheoarterial.

the surgical procedure. It was not until 1956 that Davis and Southwick [21] called attention to the problem of the tracheoarterial fistula as we know it today. They described rupture of the innominate artery after pressure-induced erosion of the tracheostomy cannula through the tracheal wall. Although not discussed herein, tracheoarterial fistula has also been described after tracheal reconstruction [22–25].

Since Schlaepfer's report in 1924, more than 140 cases of tracheoarterial fistula have been reported in the English literature. More recent literature suggests that the incidence of delayed major vessel bleeding is in fact similar to that reported in Schlaepfer's series. Of the 115 patients in that classic article, the majority had hemorrhaged from erosion into the innominate artery (72%). Other sites included common carotid artery (4.3%), the inferior thyroid artery (2.6%), the superior thyroid artery (0.9%), aortic aneurysm (1.8%), and the right innominate vein (3.5%). A source was not reported for 17 (15%). Seventy-eight percent of the 68 cases reviewed by Brantigan [26] were due to innominate artery erosion. An unknown vessel was responsible for 10%, and the carotid artery or the common trunk were responsible for another 9% of hemorrhage. Tracheocarotid fistula has been reported by others [27–29]. A single case of hemorrhage from a tracheo-right subclavian artery fistula has been reported, and a branch of the innominate trunk, the thyroid ima artery, present in 5 to 10% of normal individuals, may also be a cause of tracheoarterial hemorrhage [30].

Untreated, tracheoarterial fistulas are uniformly fatal. The literature does not report a single case of a patient who survived without surgical intervention. Death has been rapid in patients in whom the diagnosis was not entertained or in whom surgical control was not obtained in an expeditious fashion. Although it is possible that an unrecognized, misdiagnosed patient has survived, the dramatic presentation of an arterial erosion makes it highly unlikely.

The first report of successful treatment of a tracheoarterial erosion was by Silen and Spieker in 1965 [31]. This patient died from pneumonia, as did a second who died following rehemorrhage shortly after the original procedure. Reich and Rosenkrantz [32], in 1968, were the first to report a long-term survivor after massive hemorrhage and subsequent surgical repair of the tracheoinnominate artery fistula. Following this report, Biller and Ebert [33] and Mathog and colleagues [34] reported long-term survivors in 1970 and 1971, respectively. A review of the world's literature in 1976 [18] found a survival rate of 25%, having excluded patients who were "improperly resuscitated."

Yang and associates [35] reviewed 37 cases of tracheoarterial fistula, and they found an overall survival of 27%. Twelve of these patients died immediately. Of the 25 that survived to surgery, 10 were considered long-term survivors. Eight of the 25 that survived the surgical repair died from unrelated causes. The review by Nelems [36] of the English literature in 1981 reported 19 long-term survivors after a tracheoinnominate artery fistula occurred after tracheostomy. Takano and co-workers [37] also described 14 patients reported in the Japanese literature; 4 (29%) survived after interventional surgery. Since that time, there have been 17 additional reports of hemorrhage from a tracheoinnominate artery fistula; 9 patients are considered to be long-term survivors (53%) [27,35,37–40]. This higher survival may reflect earlier consideration of the diagnosis or definitive surgical therapy.

Because more patients are being managed with long-term ventilatory support, one is certain to consider the possibility of a tracheoarterial fistula in the differential diagnosis of hemorrhage from the tracheostomy. Because morbidity and mortality of such a complication are substantial, physicians caring for these patients should have a strategy by which to approach diagnosis and management of this complication.

Pathogenesis

The site of erosion of the trachea is multiple, and it includes the tracheostoma, the tracheostomy tube cuff, and the tracheostomy tube tip (Fig 1A–D). These sites are consistent despite the vascular structure involved. The usual anatomy [41,42] explains the predominance of erosions into the innominate artery, although common variants will often bring other vascular structures into close proximity of the trachea [42–46].

When the fistula forms at the tracheostoma, it can be due to the stoma being placed too low, pressure from the tracheostomy tube, or both [31,34,47–53]. When the neck is hyperextended to offer better exposure of the trachea during the operation, several tracheal rings are moved upward. As a result, the tracheal incision will be made lower than realized [31,47]. When the tracheostomy is too low, the anterior surface of the tube is placed in closer proximity to the innominate artery. Pressure applied to the wall of the artery leads to its erosion. This process may be facilitated by the continuous pulsation of the artery against the cannula, as well as by the rocking motion of the tube associated with mechanical ventilation [32,54,55], and with movement of the patient [33,56,57]. Therefore, surgeons must ensure placement of the tracheostomy tube above the 4th tracheal ring. Visualization of

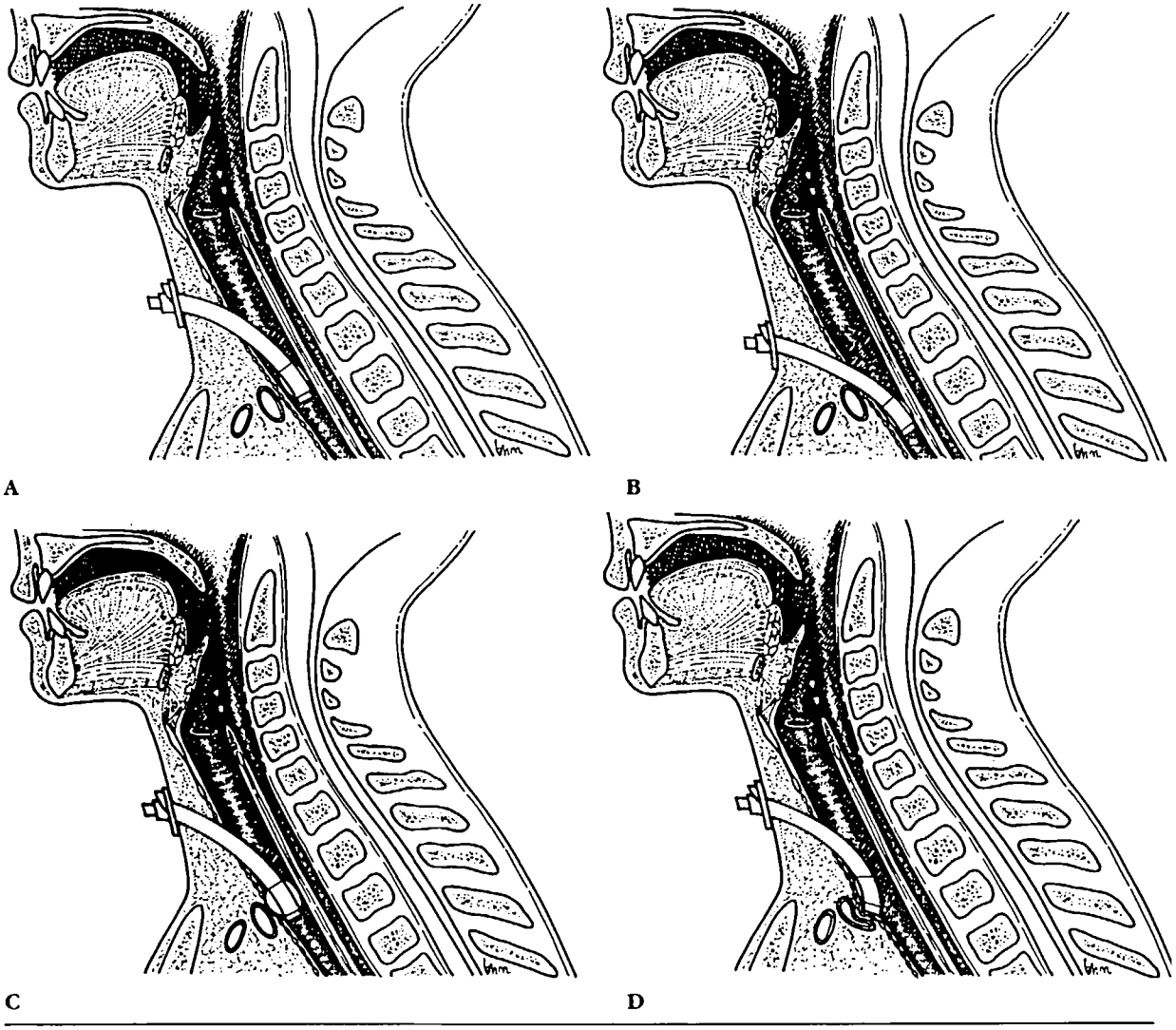

Fig 1. Anatomy of the tracheoarterial fistula. (A) Proper creation of the tracheostomy above the 4th tracheal ring; normal relationship of tracheostomy cannula and innominate vessels is shown for comparison purposes. (B) Tracheoarterial fistula at the stomal site. Erosion into the innominate artery by the inferior surface of the tracheal cannula from a low-placed tracheostomy stoma. (C) Tracheoarterial fistula at the balloon site. Erosion into the innominate artery after pressure/trauma–induced necrosis of the tracheal wall. (D) Tracheoarterial fistula at the cannula tip. Erosion into the innominate artery by the tracheostomy tube tip after its erosion through the anterior tracheal wall.

the cricoid cartilage during exposure facilitates accurate counting of the rings. Erosion at the neck of the cannula has also been described despite correct placement of the tracheostomy [50,58]. In some patients, particularly young women and children (up to 25%), the innominate artery crosses the trachea at a higher level, and it tends to be in more contact with the trachea because both structures lie in the narrowest part of the thoracic inlet [22,44]. With downward pressure exerted by the ventilator tubing, the tracheal cannula may erode through several tracheal rings, with resultant erosion of the artery despite correct placement of the tracheostoma and position of the vascular structures [59,60].

The tracheoarterial fistula can form at the level of the balloon of the tracheostomy tube [18, 29,32,50,61]. Pressure necrosis by the cuff has been implicated as the inciting event. Evidence of damage has been seen as early as 48 hours after placement of the tube [12,62], and a pathological study in dogs that used low-pressure cuffed endotracheal tubes found light and scanning electron microscopic evidence of mucosal and submucosal damage to the trachea as early as 4 hours after intubation [63]. The earliest change is superficial tracheitis; acute inflammation, hemorrhage, and fibrin deposition is seen microscopically. Small, shallow ulcerations overlying the anterior aspect of the

cartilaginous rings at the level of the cuff soon follow. The size of the ulcers increase with time, leading to exposure of the cartilaginous rings, with subsequent softening, fragmentation, and loss of the cartilage [62,64]. Other factors that would be expected to impair wound healing have also been implicated in the tracheal damage, including infection (both local and systemic), anemia, hypotension, hypoproteinemia, and corticosteroid therapy [12,18,59,65]. In general, the amount of tracheal damage increases in direct relation to the length of time on mechanical ventilation [62]. Although the length of time that the tracheostomy tube is in place is the most important factor for the development of tracheal damage in general, it is not clear that length of time is directly related to vascular injury [12].

Although the duration of time that a cuffed tracheostomy tube is in place may be important, it is likely that balloon pressure is more important in leading to tracheal damage. Early tracheostomy tube balloons were of small volume, resulting in high cuff pressures. As mean tracheal capillary perfusion pressure, estimated at 20 to 30 mm Hg [66,67], is exceeded, evidence of local ischemia and pressure necrosis develops. In a study of tracheal damage due to tracheostomy tubes, the Rusch, cuffed Jackson, and Portex tubes had cuff pressures of 120, 174, and 136 mm Hg, respectively [68]. Another study [69] found intracuff pressures for the older cuffs to average 270 mm Hg. Development of the high-volume, low-pressure cuff has been an important advance. However, despite significantly lower intracuff pressures, even the low pressure cuffs can exceed tracheal mucosal capillary perfusion pressure, particularly when high airway pressure is present [70]. These tubes have also been shown to cause tracheal damage. The degree of damage with the new tubes was proportional to the intracuff pressure [68]. It has been suggested that the tracheal damage, particularly with the high-volume, low-pressure cuffed tubes, is due to mechanical trauma, in addition to a possible ischemic insult [63,65,71]. It is unclear from the literature whether the incidence of tracheoarterial fistula has decreased with the use of low-pressure tracheostomy tube cuffs.

Lastly, the fistula can also form at the tip of the tracheostomy tube due to erosion of the anterior tracheal wall [18,21,34,48,49,55]. In a review by Jones and associates [18], up to 66% of all documented erosions were at the distal end of the cannula. Earlier tubes were fashioned with a 90-degree curvature, which easily allowed the tip to turn into the anterior wall. Movement of a poorly secured tube during mechanical ventilation has been thought to contribute to fistula formation by increasing tracheal trauma directly. Newer tubes have a smaller degree of angulation (60 degrees), which probably has reduced the incidence of tracheal erosion [38,47,51]. Although erosion of the tip is often into the innominate artery, one case documented erosion of the tip through the 9th tracheal ring into the arch of the aorta [72].

Diagnosis

Unfortunately, there are no well-validated diagnostic tests or procedures in our current armamentarium to confirm or to exclude the presence of a tracheoarterial fistula. As a result, diagnosis of a tracheoarterial fistula must rest on a high index of clinical suspicion (Table 2).

History/Examination. Typically, bleeding from or around the tracheostomy tube occurs 48 hours or more following the procedure. Its peak incidence is between the first and second week. Bleeding develops during the first 21 days in 72% of patients [18,26]. Significant hemorrhage, however, can occur quite late in a patient's course. In the series by Brantigan [26], almost 9% of hemorrhages occurred after the 6th postoperative week, and hemorrhage has occurred much later, up to 18 months postprocedure [32,73,74].

Patients may complain initially only of nonspecific symptoms, such as chest pain, cough, or retrosternal discomfort [28], but they usually have no complaints before bleeding occurs. A potentially helpful but infrequent sign is pulsation of the tracheostomy tube, indicating its proximity to an artery. First noted retrospectively by Davis and Southwick [21], and by others as well [30,31,33,56], it may be present in only 5% of patients [18]. Suspicion is heightened when the tracheostomy is low-lying and when factors that impair wound healing are present.

Compared to the oozing of capillary and venous bleeding in the immediate postoperative period,

Table 2. Clinical Clues Suggestive of Tracheoarterial Fistula

Bleeding
48 hours or more following tracheostomy
Usually brisk
May spontaneously subside
Low-lying tracheostomy tube
Pulsation of tracheostomy tube
Presence of predisposing condition: infection, hypotension, malnutrition, corticosteroid use

bleeding from an arterial source can be dramatic. It is usually brisk, possibly projectile, and it is often followed rapidly by death by exsanguination or, more likely, aspiration and asphyxiation. However, it is not uncommon that catastrophic hemorrhage is preceded by bleeding that spontaneously stops [30–32,49,56]. This sentinel bleed may be only a few milliliters or up to several hundred milliliters of blood. It has occurred as soon as 30 hours postoperatively [30]. It is very important to appreciate this prodromal sign because it has been reported in 34 to 50% of all patients [18,33,34], and life-threatening, massive hemorrhage will follow within hours to days of this first episode [18,33]. As a result, some authors believe that a patient with hemoptysis of more than 10 mL bright red blood from the tracheostoma or cannula occurring 48 or more hours after placement must be assumed to have a tracheoarterial fistula [18,47,73].

Diagnostic Procedures. Some procedures are most helpful in ruling in causes of bleeding other than the tracheoarterial fistula. Most bleeding from or around the tracheostomy tube is due to tracheitis, granulation tissue, or suction trauma, particularly in a patient with an underlying coagulopathy. Therefore, these diagnoses, as well as bleeding from pneumonia, pulmonary embolism, or other lower respiratory tract diseases, need to be systematically ruled out before subjecting a patient to a major surgical procedure to confirm the diagnosis of and to definitively treat a tracheoarterial fistula. Evaluation of hemoptysis in general is discussed elsewhere [75].

After determining that the patient is not bleeding from a superficial vessel at the external stomal site, fiberoptic bronchoscopy (FOB) can be used to evaluate the airway for evidence of friable granulation tissue, tracheitis, or diseases distal to the primary carina [12,57,76,77]. FOB should not be performed to exclude a tracheoarterial fistula. Its sensitivity as a diagnostic test appears to be low. It has failed to uncover the site even after bleeding has stopped [18,78]. If caution is not used, this procedure may destabilize the situation. Removal of clots from the tracheal wall can cause recurrent bleeding, as can deflation of the cuff or removal of the tube to inspect the tracheal wall. Finally, during active hemorrhage, the trachea is filled with blood, thus making any fiberoptic procedure difficult.

Should bronchoscopy be performed to investigate airway bleeding when the possibility of a tracheoarterial fistula has been raised, it must be performed in the operating room, preferably with a rigid bronchoscope, with the patient prepared for a possible thoracic surgical procedure [18]. If inspection of the tracheostomy wound and bronchoscopy have failed to visualize a cause for the airway bleeding, cuff deflation as a diagnostic maneuver should be done in the operating room and never at the bedside, even if the tracheostomy tube is left in place. Although temporarily deflating the balloon that is tamponading the tracheoarterial fistula may confirm the diagnosis in this setting, bleeding may be uncontrollable. Conversely, bleeding may not recur at that moment. In either case, the patient must go to the operating room for a more complete examination/definitive operation.

Angiography has been used to demonstrate a vascular abnormality. Conrad and associates [79] studied 2 patients with suspected tracheoarterial fistula with an arch aortagram. In both patients, the right posterior oblique or lateral position revealed a small extralumenal collection of contrast material representing a false aneurysm, not a true fistulous tract. Erosion into the innominate artery was confirmed by surgery in both patients. Revilla [23] showed extravasation of contrast by an arch aortagram in a patient with a tracheoinnominate artery fistula. Others [80] showed complete extravasation of contrast material into the trachea following a selective injection of the innominate artery. In contrast, when bleeding has ceased, the angiogram has been normal [18,39,49,76].

Like bronchoscopy, angiography is of very limited diagnostic use. Centers must be skilled in the procedure and its interpretation, time may not allow for it, and it has never been validated as a diagnostic tool for this problem. Its main value may be to visualize the origin of the left common carotid artery. Anatomical variants in which the left common carotid artery arises from the innominate artery occur in 15 to 37% of normal subjects. Anomalies that comprise another 1.4 to 2.4% also bring the left common carotid artery in front of the trachea [42–46,81]. Not only is this a possible source of hemorrhage, but it is also vital information to a surgeon contemplating repair. Should bleeding cease, and the patient remain hemodynamically stable, the decision to perform angiography should therefore be made by vascular or thoracic surgical consultants.

Management

Management of tracheoarterial fistula can be divided into 2 categories: (1) stabilization and supportive care, and (2) definitive treatment. Regardless of the location of the tracheal defect or the vessel involved, emergent management and supportive care do not change.

Supportive Care. First and foremost, the airway needs to be secured and protected. Hypovolemia, if present, must also be corrected with rapid intravenous infusion of crystalloid or colloid. Blood, when available, should be transfused to maximize oxygen delivery.

An attempt to tamponade the bleeding site should be made by immediate overinflation of the tracheostomy tube balloon, with simultaneous retraction of the tube anteriorly (Fig 2). Such a procedure can be both therapeutic and diagnostic but it is only a temporizing measure that allows time for more definitive therapy. Although the site of bleeding may not be at the site of the cuff, and thus the maneuver not expected to stop the hemorrhage, it should be tried because it has been reported to successfully control bleeding in more than 80% of patients in one review [18].

If the bleeding has stopped, blood must be aspirated from the airway below, and an endotracheal tube should be placed, with the balloon more distal than the tracheostomy tube. Further diagnostic evaluation can then take place. Should bleeding persist despite attempts at cuff overinflation, an endotracheal tube must be placed to protect the airway, distal to the tracheostomy tube, just as the tracheostomy tube is removed. If oral intubation is difficult due to massive hemorrhage, passage of a pediatric endotracheal tube through the patient's tracheostomy cannula will provide adequate oxygenation and ventilation as preparations are made for urgent surgical intervention.

A "bedside" procedure, first proposed by Utley and colleagues [51], might be attempted if cuff inflation fails to stop the bleeding. They suggested that after securing the airway, blunt dissection, with a finger, via the tracheostoma, should be performed to remove the innominate artery from the anterior wall of the trachea. To avoid tearing the artery, the finger should press against the trachea during dissection, which allows for direct tamponade of the artery against the sternum (Fig 3). Direct pressure is maintained until the patient can be transported to the operating room for a more definitive procedure. This procedure was also used to tamponade hemorrhage from a tracheo-right common carotid artery fistula [82]. Alternatively, the skin and the superficial fascia can be entered through a short right infraclavicular incision. The mediastinum can be dissected, and the innominate artery can be occluded by finger compression. Thoracic surgeons adept at mediastinoscopy are perhaps most comfortable with these techniques. They should not be attempted by most physicians who care for tracheotomized patients. However, once the airway is secured, it might be easier to effect a similar result by inserting a finger into the distal trachea via the tracheostoma and applying ventral pressure as long as the finger does not totally occlude the airway.

Meyers and Pilch [83] describe a patient in whom they extended the tracheotomy incision proximally. The upper two tracheal rings, the thyroid isthmus, the cricoid cartilage, and the cricothyroid membrane were divided in the midline, and the proximal trachea was opened. The trachea was packed with

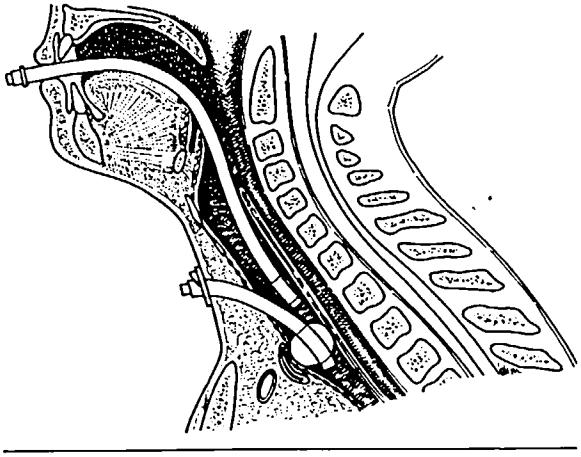

Fig 2. Emergency management. Attempt to tamponade bleeding by overinflation of tracheostomy tube balloon. Tracheal tube is simultaneously pulled forward. Orotracheal tube is positioned above tracheostomy tube. Should bleeding continue, endotracheal tube is pushed distally, and the tracheostomy tube is removed in a quick, coordinated fashion.

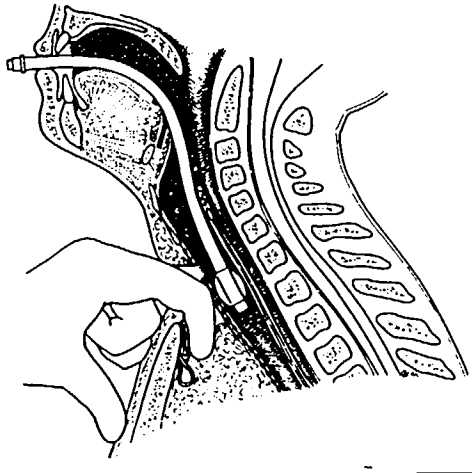

Fig 3. Emergency management. Direct digital tamponade of innominate artery. Occlusion of the innominate artery by digital compression against the sternum following blunt dissection of the artery from the anterior tracheal wall, as first described by Utley and colleagues [51].

subsequent tamponade of the hemorrhage. Clearly, this procedure must be performed by skilled hands. Should the patient survive repair of the tracheoarterial fistula, tracheal reconstruction would be required because division of the cricoid cartilage often will result in laryngeal instability.

Takano and co-workers [37] used a 5 French Fogarty catheter inserted through the right brachial artery and passed to the innominate artery under fluoroscopic guidance to balloon-occlude the suspected site of hemorrhage after bleeding was temporarily stopped with tracheostomy tube cuff overinflation. Complete hemostasis was obtained with this procedure, and the patient was taken immediately to the operating room. A similar approach was suggested by Nunn and associates [84].

Definitive Treatment. The approach most preferred for definitive management of a tracheoarterial fistula is the median sternotomy, which gives the best exposure of the entire supra-aortic trunk. More limited procedures, such as a partial median sternotomy with or without horizontal extension into the right third or fourth intercostal space, have also been used [36,50,85]. Ramash and Gazzaniga [72] used 2 small incisions in the anterior thorax and neck, and a single case report describes control of hemorrhage by application of Weck vascular clips placed via a suprasternal incision [86]. These latter procedures may avoid the risk of complications that are associated with operating in a contaminated field. In a review of sternotomy complications Serry and colleagues [87] found an overall frequency of sternal wound complications of 1.8%. A predisposing factor was the presence of a tracheostomy, perhaps reflecting the underlying debility of these patients. Mortality ranged from 7.6% when serous drainage only was present, to 71% with infection with sternal dehiscence. Yang and associates [35] report a frequency of complete sternal wound dehiscence of 8% in patients who survived an operation for tracheoinnominate artery fistula.

After induction of general anesthesia, both the chest and the anterior neck are prepared, with both sides of the neck included in the surgical field. Prophylactic intravenous antibiotics should be given. The chest is opened, and the mediastinum is exposed. The vascular anatomy, particularly its variants, must be confirmed. Statistically, erosion into the innominate artery is by far the most likely source of hemorrhage. For that reason, attention is devoted to its repair.

The innominate artery is isolated with control of the proximal and the distal ends should rebleeding occur. The right subclavian and the common carotid arteries are then exposed. The distal innominate artery is mobilized from the trachea, which often results in rebleeding and assures the diagnosis, and the area of erosion is then confirmed.

Once adequate exposure is obtained, the surgeon has a choice of several operative procedures, including ligation, resection of a segment of the innominate artery and oversewing the ends, interposition grafting with saphenous or innominate vein [47,84], and direct vascular repair by suture or by vein patch [35,78]. Most surgeons have chosen to resect the artery and to oversew the ends [18,31,32,34,39,76,80]. The stumps are allowed to retract away from the infected field [50]. Interposition of healthy, well-vascularized tissue between the trachea and the resected artery with a pedicled strap or sternocleidomastoid muscle flap, or pleural or pericardial flaps is recommended [24,32,33, 76,77]. Attempts to repair or suture the artery, which must be considered septic, have been followed by bleeding at the suture line, rehemorrhage, and death [22,31,49,73,76,78,85]. For this reason, such a conservative procedure should not be undertaken.

Not surprisingly, the type of operation performed is one of the most important determinants of outcome, second only to immediate control of the airway and hemorrhage. The postoperative rebleeding rate is significantly lower after interruption of the innominate artery (7%) than after procedures that maintain its continuity (60%) [35]. Because postoperative bleeding is almost always fatal, it follows that the survival rate at 2 months is significantly higher with innominate artery interruption (64–77%) than without (6–10%) [18,35].

If no restorative procedure is planned, the subclavian and the right common carotid should be divided and ligated separately to avoid a subclavian steal phenomenon [18,33,39,74,78], although clinically, this complication may not be a problem [50,88]. If division is not performed, the innominate artery is ligated 1 cm before its bifurcation. When the left common carotid originates from the innominate artery, its ligation must take place immediately after the bifurcation. If this approach is not possible, a restorative procedure for the left common carotid artery must be performed [39]. Finally, prior to closure, the area of dissection is irrigated with antibiotic solution and drained by mediastinal catheters.

Because of the concern that arterial insufficiency can result in neurological compromise to the right upper extremity, as well as to areas supplied by the right common carotid artery [89,90], attempts are made to assess collateral flow once flow from

the innominate artery ceases. Although animal studies have shown as much as an 18% decrease in cerebral blood flow after innominate occlusion [91], published experience dictates that this decrease is not a problem [18,22,31–36,50,53,74,92], a finding confirmed in laboratory animals [91,93]. In one review, evidence of neurological deficit was found in only 1 of 22 (4.5%) patients surviving fistula repair [18]. Although Biller and Ebert [33] suggest an expected neurological complication rate of 20 to 30%, no supportive evidence is given.

Collateral flow is provided by the right intercostal and the internal mammary arteries, as well as the intracranial anastomoses from the left carotid and vertebral arteries. Collateral cerebral blood flow is often adequate in young individuals, although it may not be so in periods of extreme hypotension. Obviously, restoration of circulating blood volume as rapidly as possible is important in this regard. Evidence for adequate collateral circulation includes good back flow after clamping of the artery; palpable pulses in the right carotid, superficial temporal, axillary, and radial arteries; and pupillary response under light anesthesia. Use of electroencephalographic monitoring at the time of innominate occlusion to monitor cerebral function has been recommended [40,77,94]. Carotid stump pressure should be measured after clamping the innominate artery [47,72]. If stump pressure is found to be below 50 mm Hg, a bypass procedure should be considered.

Bypass locally can be performed by using an artificial prosthesis [31] or autologous material [23,72,79,84,94]. Because the anastomosis is in a potentially infected area, the latter is preferred, because infection can destroy an initially successful procedure. Takano and colleagues [37] performed aorto-right common carotid bypass with a prosthetic graft, passing the graft under the right clavicle in an attempt to avoid contact with the tracheal fistula. Bypass procedures, if required, are best carried out away from the infected field. Distal axillo-axillary, femoral-right axillary, and carotid-carotid bypass have all been performed [31,39,49,50, 95–97].

Repair of the tracheal defect can be carried out primarily [18,39,76,94], or the erosion can be allowed to heal secondarily [18,31,34,50]. There is no clear benefit to one or the other procedure. Fibrin adhesive has been used to successfully close the tracheal defect of an acquired tracheoesophageal fistula [98]. This may be an alternative, though extremely limited, method of repair of the tracheal defect. Continued mechanical ventilation can be carried out with an endotracheal tube with the balloon at a different site, or with a new tracheostomy tube with the stoma at a higher site.

Prevention

The best therapy for a tracheoarterial fistula is its prevention, which depends on avoidance of unnecessary tracheostomies, proper surgical technique, and meticulous tracheostomy care. Tracheostomy should never be a disorganized procedure; adequate lighting, suction, assistance, and surgical expertise are required. Indications and timing of tracheostomy are discussed elsewhere [4,5,99]. As discussed previously, tracheoarterial fistulas occur at 3 sites: the tracheostoma, the cannula cuff, and the cannula tip. Preventive measures must therefore be directed toward these areas.

Whenever a tracheostomy is performed, care must be taken to ensure correct placement of the tracheostoma and the tube. The incision level is important because this location directs the angle of dissection into the trachea [94]. A wide incision is necessary so that one can inspect and palpate adjacent tissues for abnormally placed vessels. Excessive extension of the head and neck must be avoided. The tracheostoma should be created above the 4th tracheal ring and ideally placed at the second or third tracheal ring. The tube must be secured properly, and tension on the ventilator tubing should be minimized. If excessive movement by the patient results in excessive traction on the tubing, sedation should be prescribed. Pulsation of the tracheostomy tube should be taken as a sign of its proximity to a major vessel, and thought should be given to placement of the tracheostoma at a different site, or, if not possible, exchange of the tube with one of a shorter length. Dellen and colleagues [100] used muscle flaps to create a permanent tracheostomy and to protect the innominate artery when evaluation of a pulsating tube revealed the artery just inferior to the widened tracheostoma.

Currently, only high-volume, low-pressure cuffed tubes should be used. Intracuff pressure is easy to measure with a manometer connected to the cuff-inflating tube via a 3-way stopcock [101–103], and cuff pressure should ideally be kept below 20 to 30 mm Hg. One study found significantly lower pressures if balloon inflation and pressure measurements were not done simultaneously [101]. The pressure exerted against the tracheal wall by the large-volume, thin-walled cuffs had been thought to be equal to the intracuff pressure. However, this equality probably is not always the case; on occasion, intracuff pressure may overestimate

lateral tracheal wall pressure [104, 105]. In situations in which static compliance is low, such as in patients with adult respiratory distress syndrome, high airway pressure is transmitted to the cuff, ideal cuff pressure is exceeded [80], and it is presumably transmitted to the tracheal wall.

A reliable seal of the trachea is needed for both effective ventilation and prevention of macroaspiration. Although intracuff and perhaps lateral wall pressures may remain high with the minimal leak technique [106], this technique in most instances allows one to balance the need to seal and to protect the airway with the need to minimize tracheal wall damage. Physicians caring for tracheostomized patients must choose a method of assessing tracheostomy tube cuff pressure, ideally by use of a manometer for direct pressure measurement, or by use of the minimal leak (occluding pressure) technique. Balloons should not be indiscriminately inflated without regard for intracuff pressure and possible tracheal wall damage. Intermittent cuff deflation does not prevent tracheal damage [107,108]; therefore, the balloon should be left inflated, not blown up and down, as the cuff is frequently overinflated by inexperienced personnel [109].

Because tracheal wall damage can be due to the cannula tip, it is most important that the tracheostomy tube be secured. This problem remains despite use of the newer, less angulated tracheostomy tubes. One author suggests that fiberoptic tracheoscopy be performed when a tracheostomy tube is changed for the first time, so that evidence of pressure necrosis or mucosal erosion at any of the 3 potential sites can be identified and corrective measures instituted [57]. This approach has never been evaluated in a prospective fashion.

Recently, use of percutaneous, bedside tracheostomy has been advocated. Its advantages [110–112] and disadvantages [113–115] have been reported elsewhere. This is a relatively new technique, and, combined with the low incidence of tracheoarterial fistula, there have been no reports of arterial hemorrhage as a complication of this procedure. However, with emergent placement of these tubes, by perhaps less skilled physicians, it is likely that arterial hemorrhage will soon be cited as a complication.

Finally, because of the role of infection in formation of tracheal damage, care must be paid to a patient's immunological status, and tracheal infection should be treated aggressively. The effects of adequate nutrition on immunocompetence, wound healing, and response to infection are well known. Therefore, nutrition for this and other reasons should be optimized.

Summary

Tracheoarterial fistula is a life-threatening, but fortunately rare complication of tracheostomy. It occurs with a frequency of approximately 0.7%. Its consequences are devastating, with an extremely high case fatality ratio. Because signs and symptoms, as well as diagnostic tests and procedures, are usually not helpful, diagnosis depends on maintaining a high index of clinical suspicion. Higher survival rates from this dreaded complication have been shown if rapid identification and correct emergency measures are instituted. Surgeons, intensivists, and others who routinely deal with tracheostomies must be aware that a tracheoarterial fistula is a complication of the procedure, and they must be thoroughly familiar with prevention, diagnosis, and management of this catastrophic event.

References

1. Eavey RD. The evolution of tracheotomy. In: Tracheotomy. Myers EN, Stool SE, Johnson JT, eds. New York: Churchill Livingstone, 1985:1–11
2. Frost EAM. Tracing the tracheostomy. Ann Otol 1976;85:618–624
3. Heffner JE, Miller KS, Sahn SA. Tracheostomy in the intensive care unit. Part 1: indications, technique, management. Part 2: complications. Chest 1986;90:269–274;430–436
4. Lewis RJ. Tracheostomies. Indications, timing and complications. Clin Chest Med 1992;13:137–149
5. Silva WE, Hughes J. Tracheotomy. In: Intensive care medicine, ed 2. Rippe JM, Irwin RS, Alpert JS, Fink MP, eds. Boston: Little, Brown, 1991:169–182
6. Yarrington CT, Frazer JP. Complications of tracheostomy. Arch Surg 1965;91:652–655
7. Stauffer JL, Olsen DE, Petty TS. Complications and consequences of endotracheal intubation and tracheotomy. A prospective study of 150 critically ill adult patients. Am J Med 1981;70:65–76
8. Meade JW. Tracheotomy—its complications and their management. N Engl J Med 1961;265:519–523
9. Goldstein SI, Breda SD, Scheider KL. Surgical complications of bedside tracheotomy in an otolaryngology residency program. Laryngoscope 1987;97:1407–1409
10. Astrachian DI, Kirchner JC, Goodwin WJ. Prolonged intubation vs tracheotomy: complications, practical and psychological considerations. Laryngoscope 1988;98: 1165–1169
11. Head JM. Tracheostomy in the management of respiratory problems. N Engl J Med 1961;264:587–591
12. Rogers LA. Complications of tracheostomy. South Med J 1969;62:1496–1500
13. Arola MK. Tracheostomy and its complications. Ann Chir Gynecol 1981;70:96–106
14. Mulder DS, Rubush JL. Complications of tracheostomy: relationship to long term ventilatory assistance. J Trauma 1969;9:389–400

15. Oliver P, Richardson JR, Clubb RW, Flake CG. Tracheotomy in children. N Engl J Med 1962;267:631–637
16. Stowe DG, Kenan PD, Hudson WR. Complications of tracheostomy. Am Surg 1970;13:34–38
17. McClelland RMA. Complications of tracheostomy. Br Med J 1965;2:567–569
18. Jones JW, Reynolds M, Hewitt RL, Drapanas T. Tracheo-innominate artery erosion: successful surgical management of a devastating complication. Ann Surg 1976;184:194–204
19. Körte W. Uber einige seltenere nachkrankheiten, nach der tracheotomie wegen diphtheritis. Arch Klin Chir 1879; 24:238–261
20. Schlaepfer K. Fatal hemorrhage following tracheotomy for laryngeal diphtheria. JAMA 1924;82:1581–1583
21. Davis JB, Southwick TW. Hemorrhage as a postoperative complication of tracheostomy. Ann Surg 1956;144: 893–896
22. Deslauriers J, Ginsberg RJ, Nelems JM, Pearson FG. Innominate artery rupture. A major complication of tracheal surgery. Ann Thorac Surg 1975;20:671–677
23. Revilla AG, Donahoo JS, Cameron JL. Tracheal-innominate artery fistula after tracheal reconstruction. A case of a successful repair. J Thorac Cardiovasc Surg 1974;67:629–633
24. Arbulu A, Thoms NW. Tracheal-innominate artery fistula after repair of tracheal stenosis, problem and prevention. J Thorac Cardiovasc Surg 1974;67:936–940
25. Neville WE, Bolanowski PJP, Soltanzedah H. Prosthetic reconstruction of the trachea and carina. J Thorac Cardiovasc Surg 1976;72:525–536
26. Brantigan CO. Delayed major vessel hemorrhage following tracheostomy. J Trauma 1973;13:235–237
27. Edelson RJ, Locicero J. Delayed hemorrhage from an anomalous carotid artery following tracheostomy. Am Surg 1989;55:488–491
28. Schenken JR, Brown JM. Tracheocarotid fistula with fatal hemorrhage following tracheotomy for poliomyelitis. J Pediatr 1954;45:94–97
29. Comer TP, Raskind R, Schmalhorst WR, Arbegast NR. Delayed massive hemorrhage from tracheostomy. J Cardiovasc Surg 1974;15:389–391
30. Willerson JT, Fred HL. Delayed fatal hemorrhage after tracheotomy. Arch Intern Med 1965;116:138–141
31. Silen W, Spieker D. Fatal hemorrhage from the innominate artery after tracheostomy. Ann Surg 1965;162:1005–1012
32. Reich MP, Rosenkrantz JG. Fistula between innominate artery and trachea. Arch Surg 1968;96:401–402
33. Biller HF, Ebert PA. Innominate artery hemorrhage complicating tracheotomy. Ann Otol Rhinolaryngol 1970;79: 301–306
34. Mathog RH, Kenan PD, Hudson WR. Delayed massive hemorrhage following tracheostomy. Laryngoscope 1971;81: 107–119
35. Yang FY, Criado E, Schwartz JA, et al. Trachea-innominate artery fistula: retrospective comparison of treatment methods. South Med J 1988;81:701–706
36. Nelems JMB. Tracheo-innominate artery fistula. Am J Surg 1981;141:526–527
37. Takano H, Ihara K, Sato S, et al. Tracheo-innominate artery fistula following tracheostomy. Successful surgical management of a case. J Cardiovasc Surg 1989;30:860–863
38. Petrek JA, Bains MS, Spiro RS. Innominate artery fistula caused by laryngectomy tube. South Med J 1983;76:672–674
39. Tournigand P, Djurakdjian S, Jajah S, Morisset P. Successful surgical repair of a tracheo innominate fistula: tactical considerations. J Cardiovasc Surg 1982;23;247–251
40. Brewster DC, Moncure AC, Darling C, et al. Innominate artery lesions: problems encountered and lessons learned. J Vasc Surg 1985;2:99–110
41. Gray H. The arteries. In: Goss CM, ed. Anatomy of the human body. Philadelphia: Lea & Febiger, 1973:576–577
42. McVay CB. Surgical anatomy. Philadelphia: WB Saunders, 1984:426–431
43. Scheldrup EW. Vascular anomalies of the retro-infrahyoid (pretracheal) space and their importance in tracheotomy. Surg Gynecol Obstet 1957;105:327–331
44. Jarvis JF. Vascular hazards in tracheostomy. J Laryngol Otol 1965;78:781–784
45. Hewitt RL, Brewer PL, Drapanas T. Aortic arch anomalies. J Thorac Cardiovasc Surg 1970;60:746–753
46. DeGaris CF, Black SB, Rieman Schneider EA. Patterns of the aortic arch in american white and negro stocks, with notes on certain other mammals. J Anat 1932;67:59–61
47. Arola MK, Inberg MV, Sotarauta M, Vanttinen E. Tracheoarterial erosion complicating tracheostomy. Ann Chir Gynecol 1979;68:9–17
48. Potondi A. Pathomechanism of haemorrhages following tracheotomy. J Laryngol Otol 1969;83:475–484
49. Myers WO, Lawton BR, Sautter RD. An operation for tracheal-innominate artery fistula. Arch Surg 1972;105: 269–273
50. Cooper JD. Trachea-innominate artery fistula: successful management of 3 consecutive patients. Ann Thorac Surg 1977;24:439–447
51. Utley JR, Singer MM, Roe BB, et al. Definitive management of innominate artery hemorrhage complicating tracheostomy. JAMA 1972;220:577–579
52. Ivankovic AD, Thomsen S. Rattenborg CC. Fatal hemorrhage from the innominate artery after tracheostomy. Br J Anaesth 1969;41:450–452
53. Golz A, Goldsher M, Eliacher I, Joachims HZ. Fatal haemorrhage following a misplaced tracheostomy. J Laryngol Otol 1981;95:529–533
54. Hood RM. Rush CE. Lethal hazards of the Morch respirator. J Thorac Cardiovasc Surg 1962;43:338–342
55. Lunding M. The tracheotomy tube and postoperative tracheotomy complications. Acta Anaesth Scand 1964;8: 181–189
56. Mehalic TF, Farhat SM. Tracheoarterial fistula: a complication of tracheostomy in patients with brain stem injury. J Trauma 1972;12:140–143
57. Mamikunian C. Prevention of delayed hemorrhage after tracheotomy. Ear Nose Throat J 1988;67:881–892
58. Conn J Jr, Tolis GA, Shields TW. Fatal hemorrhage following tracheostomy. IL Med J 1969;135:27–29
59. Barton TK, Gaede JT. Recurrent arteriotracheal fistula. South Med J 1980;73:687–688
60. Majeski JA, MacMillan BG. Tracheo-innominate artery erosion in a burned child. J Trauma 1978;18:137–139
61. Pathak PN. Rare complication of tracheostomy: erosion of innominate artery. Br Med J 1969;2:426
62. Cooper JD, Grillo HC. The evolution of tracheal injury due to ventilatory assistance through cuffed tubes: a pathologic study. Ann Surg 1969;169:334–348
63. Schmidt WA, Schaap RN, Mortensen JD. Immediate mucosal effects of short-term, soft-cuff, endotracheal intubation. A light and scanning electron microscopic study. Arch Pathol Lab Med 1979;103:516–521
64. Stiles PJ. Tracheal lesions after tracheostomy. Thorax 1965;20:517–522
65. Pearson FG, Goldberg, M, DaSilva AJ. A prospective study of tracheal injury complicating tracheostomy with a cuffed tube. Ann Otol Rhinol Laryngol 1968;77:867–882

66. Björkerud S, Ekedahl C, Hansson PG, et al. Experimental tracheal wall injury. Acta Otolaryngol 1973;75:387–388
67. Nordin U, Lindholm C-E, Wolgast M. Blood flow in the rabbit tracheal mucosa under normal conditions and under the influence of tracheal intubation. Acta Anaesth Scand 1977;21:81–94
68. Ching NPH, Ayres SM, Spina RC, Nealon TF. Endotracheal damage during continuous ventilatory support. Ann Surg 1974;179:123–127
69. Grillo HC, Cooper JD, Geffin B, Pontoppidan H. A low-pressure cuff for tracheostomy tubes to minimize tracheal injury. A comparative trial. J Thorac Cardiovasc Surg 1971;62:898–907
70. Guyton D, Banner MJ, Kirby RR. High volume, low-pressure cuffs. Are they always low pressure? Chest 1991;100:1076–1081
71. Andrews MJ, Pearson FG. Incidence and pathogenesis of tracheal injury following cuffed tube tracheostomy with assisted ventilation: analysis of a two-year prospective study. Ann Surg 1971;173:249–263
72. Ramesh M, Gazzaniga AB. Management of tracheo-innominate artery fistula. J Thorac Cardiovasc Surg 1978; 75:138–140
73. Adolfsson R, Winblad B, Östberg Y. Survival after haemorrhage from the brachiocephalic truncus following tracheostomy. Acta Otolaryngol 1975;80:312–316
74. Weissman BW. Tracheo-innominate artery fistula. Laryngoscope 1974;84:205–209
75. Irwin RS, Curley FJ. Hemoptysis. In: Intensive care medicine, ed 2. Rippe JM, Irwin RS, Alpert JS, Fink MP, eds. Boston: Little, Brown, 1991:513–524
76. Lane EE, Temes GD, Anderson WH. Tracheal-innominate artery fistula due to tracheostomy. Chest 1975;68:678–683
77. Bloss RS, Ward RE. Survival after tracheoinnominate artery fistula. Am J Surg 1980;139:251–253
78. Selking Ö, Hallén A, Lindholm CE. Management of the innominate artery hemorrhage—a complication following tracheostomy. Acta Chir Scand 1977;143:489–491
79. Conrad MR, Cameron J, White RI. The role of angiography in the diagnosis of tracheal-innominate artery fistula. Am J Roentgenol 1977;128:35–38
80. Elyaderani MK, Gabriele OF. Unique angiographic demonstration of tracheal-innominate artery fistula. South Med J 1980;73:515–516
81. Rood SR. Anatomy for tracheotomy. In: Tracheotomy. Myers EN, Stool SE, Johnson JT, eds. New York: Churchill Livingstone, 1985;89–97
82. Fox JL. Control of common carotid and innominate artery hemorrhage complicating tracheostomy. J Neurosurg 1973;38:394
83. Myers RS, Pilch YH. Temporary control of tracheal-innominate artery fistula. Ann Surg 1969;170:149–151
84. Nunn DB, Sanchez-Salazar AA, McCullagh JM, Renard A. Trachea-innominate artery fistula following tracheostomy. Successful repair using an innominate vein graft. Ann Thorac Surg 1975;20.698–702
85. Rydberg B, Gunderson O, Grumstedt B. Erosion of the innominate artery. A complication of tracheostomy. Acta Chir Scand 1972;138:537–538
86. Raskind R, Glover MB, Arbegast NR, Comer TP. Control of hemorrhage from the innominate artery complicating tracheostomy through a suprasternal approach. Vasc Surg 1973;7:265–268
87. Serry C, Bleck PC, Javid H, et al. Sternal wound complications. Management and results. J Thorac Cardiovasc Surg 1980;80:861–867
88. Killen DA, Gobbel WG. Subclavian steal-carotid recovery phenomenon. J Thorac Cardiovasc Surg 1965;50:421–426
89. Killen DA, Foster JH, Gobbel WG, et al. The subclavian steal syndrome. J Thorac Cardiovasc Surg 1966;51:539–560
90. Mozersky DJ, Barnes RW, Sumner DS, Strandness DE. Hemodynamics of innominate artery occlusion. Ann Surg 1973;178:123–127
91. Handa J, Ishikawa S, Huber P. Experimental production of the "subclavian steal." Electromagnetic flow measurements in the monkey. Surgery 1965;58:703–712
92. Grillo HC. Surgery of the trachea. Curr Prob Surg 1970;7:1–59
93. Eklöf B, Schwartz SI. Effects of subclavian steal and compromised cephalic blood flow on cerebral circulation. Surgery 1970;68:431–441
94. Weiss JB, Ozment KL, Westbrook KC, Williams GD. Tracheal-innominate artery fistula: successful management of two cases. South Med J 1976;69:430–432
95. Donohoo JS. Trachea-innominate artery fistula: successful management of 3 consecutive patients. Ann Thorac Surg 1977;24:439–447
96. Ehrenfeld WK, Levin SM, Wylie EJ. Venous crossover bypass grafts for arterial insufficiency. Ann Surg 1968;167: 287–291
97. Jacobson JH, Mozersky DJ, Mitty HA, Brothers MJ. Axillary-axillary bypass for the "subclavian steal" syndrome. Arch Surg 1973;106:24–27
98. Antonelli M, Cicconetti F, Vivino G, Gasparetto A. Closure of a tracheoesophageal fistula by bronchoscopic application of fibrin glue and decontamination of the oral cavity. Chest 1991;100:578–579
99. Heffner JE. Medical indications for tracheotomy. Chest 1989;96:186–190
100. Dellen AL, Wells JH, Cowley RA. A surgical procedure to prevent tracheo-innominate artery erosion. J Trauma 1978;18:550–553
101. Cox PM, Schatz ES. Pressure measurements in endotracheal cuffs: a common error. Chest 1974;65:84–87
102. Lindholm CE. Choice of tracheotomy tube. In: Tracheotomy. Myers EN, Stool SE, Johnson JT, eds. New York: Churchill Livingstone, 1985;125–146
103. Carroll RG, Grenvik A. Proper use of large-diameter large-residual-volume cuffs. Crit Care Med 1973;1:153–154
104. Lee T-S. Routine monitoring of intracuff pressure. Chest 1992;102:1309
105. Black AMS, Seegobin RD. Pressures on endotracheal tube cuffs. Anaesthesia 1981;36:498–511
106. Off D, Braun SR, Tompkins B, Bush G. Efficacy of the minimal leak technique of cuff inflation in maintaining proper intracuff pressures for patients with cuffed artificial airways. Respir Care 1983;28:1115–1120
107. Bryant CR, Tinkle JK, Dubilier L. Reappraisal of tracheal injury from cuffed tracheostomy tubes. JAMA 1971;215: 625–628
108. Powaser MM, Brown MC, Chezem J, et al. The effectiveness of hourly cuff deflation in minimizing tracheal damage. Heart Lung 1976;5:734–741
109. Shelly WM, Dawson RB, May IA. Cuffed tubes as a cause of tracheal stenosis. J Thorac Cardiovasc Surg 1969;57:623–627
110. Griggs WM, Myburgh JA, Worthley LIG. A prospective comparison of a percutaneous tracheostomy technique with standard surgical tracheostomy. Intensive Care Med 1991;17:261–262
111. Hazard P, Jones C, Benitone J. Comparative clinical trials of standard operative tracheostomy with percutaneous tracheostomy. Crit Care Med 1991;19:1018–1024

112. Ciaglia P, Graniero KD. Percutaneous dilational tracheostomy. Results and long term follow up. Chest 1991;101: 464–467
113. Hutchinson RC, Mitchell RD. Life-threatening complications from percutaneous dilational tracheostomy. Crit Care Med 1991;19:118–120
114. Mathisen DJ. Percutaneous tracheostomy. A cautionary note. Chest 1990;98:1049
115. Skowronski GA, Bertsen AD, Vedig AE. Bleeding risk with percutaneous tracheostomy. Anaesth Intern Care 1990; 18:273